

Non-invasive planning of endovascular procedures in patients with peripheral arterial occlusive disease: value of 125 μm^3 spatial resolution steady state MRA with a blood pool contrast agent

Winfried Albert Willinek¹, Jack Boschewitz¹, Dariusch Reza Hadizadeh¹, Guido Matthias Kukuk¹, Ute L Fahlenkamp¹, Jürgen Gieseke^{1,2}, Carsten Meyer¹, Kai Wilhelm¹, and Hans Heinz Schild¹

¹Radiology, University of Bonn, Bonn, NRW, Germany, ²Clinical Scientist, Philips Healthcare, Best, Netherlands

Aim of the study:

The purpose of this study was to evaluate the usefulness of high spatial resolution MRA with a BPCA for the planning of endovascular interventions in patients with PAOD.

Introduction:

Peripheral arterial occlusive disease (PAOD) is a common disease with a prevalence of 3-10% in the general population reaching 15-20% in individuals older than 70 years¹. Among those patients critical limb ischemia (PAOD grade III-IV) accounts for ~12,000-25,000 new cases per year resulting in annual amputation rates of ~2,500-10,000²⁻³. Endovascular treatment including percutaneous transluminal angioplasty (PTA) and stent implantation is the method of choice and an alternative to surgical procedures²⁻³. For optimal selection of candidates for endovascular interventions, exact localization, number of lesions ("index lesions") and extent and severity of the index lesions is essential²⁻³. Contrast-enhanced MR angiography (MRA) has been described to allow for diagnosis of PAOD, but with standard techniques acquired during the first pass of a contrast bolus passage, spatial resolution is limited. Steady state MRA with blood pool contrast agents (BPCA) overcomes this limitation by offering a prolonged time window for imaging that allows for increased spatial resolution⁴⁻⁵ with improved sensitivity and specificity of stenosis grading in PAOD patients⁶.

Methods:

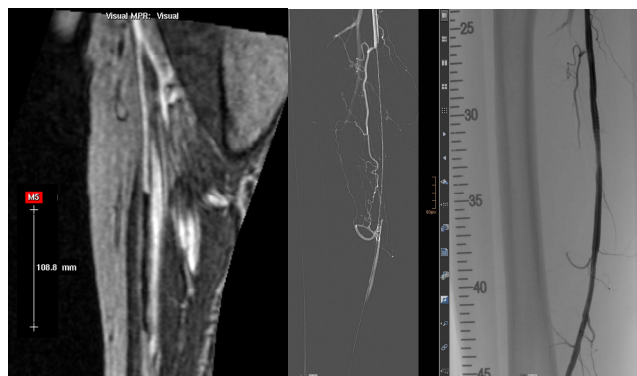
Patients with critical limb ischemia who were scheduled for an endovascular procedure based on clinical findings including ankle-brachial-index (ABI) and duplex ultrasound (DUS) were included. 10 patients (mean age: 73.1 \pm 10 years; range, 63-83 years; 9 men) were examined with the blood-pool contrast agent (BPCA) Gadofosveset Trisodium at a standard single dose and a flow rate of 1.2 ml/sec. Peripheral MRA was performed on a 1.5 Tesla system (Achieva, Philips Healthcare, Best, NL) with high spatial resolution steady state imaging [(0.49 x 0.49 x 0.48) mm³ (~ 125 μm^3); TR, TE, FA; 7.4, 2.4, 25°]⁶⁻⁷. For intraindividual comparison, catheter angiography (DSA) was obtained during the subsequent endovascular procedure. Revised TASC criteria were used to classify lesions on an intention-to-treat basis. One reader evaluated the MRA images regarding site of puncture, preferred procedure (antegrade versus retrograde), number of index lesions and length of occluded vessel segments (as a basis for selection of appropriate endovascular stents). A second independent reader who was not involved in the MRA readings assessed the DSA images in the same way. Means of the measured length of vessel occlusion and length of the implanted stents were calculated. By using the actual endovascular procedure as standard of reference (SOR), results of MRA and DSA readings were compared intraindividually.

Results:

A total of 16 index lesion were determined by MRA and confirmed by DSA (TASC A, n=10; B, n=4; C, n=2). Endovascular interventions were as follows: PTA, n=10; PTA and stent, n=6. In 2/10 patients the site of puncture/preferred procedure was changed as MRA results revealed additional index lesions in the pelvis that were not suspected based on the clinical findings: in both patients left popliteal index lesions were suspected and antegrade punctures were planned; however, MRA showed additional index lesions in the pelvis on the same site that were subsequently confirmed by DSA and treated by stent implantation after retrograde puncture to improve the inflow into the leg. Mean lengths of occluded vessel segments and of implanted stents were 37.29 \pm 50.65 mm (MRA) and 37.57 \pm 54.65 mm (DSA), respectively, with a very good intraindividual match (6/6) taking into account the margin that is needed both proximal and distal to the occluded segment.

Discussion:

High spatial resolution peripheral MRA with a blood pool contrast agent improves pre-interventional planning of endovascular procedures in patients with critical limb ischemia and may influence therapeutic decision making and reduce radiation exposure and consumption of iodinated contrast agents during the intervention.



Comparison between steady state MRA (left) for pre-interventional planning and DSA (center, right) in a 70 yo patient: occlusion of 111 mm was detected in the AFS and a 6/140 mm stent was implanted.

References:

- 1 Selvin E et al. Circulation 2004; 110; 738-743
- 2 TASC. Management of PAD. J Vasc Surg 2000; 31: S1-S287
- 3 TASC II. Eur J Vasc Endovasc Surg 2007; 33: S1-74
- 4 Grist TM et al., Radiology 1998; 207:539-544
- 5 Rapp JH et al., Radiology 2005; 236:71-78;
- 6 Hadizadeh DR et al., Radiology 2008; 249:701-711
- 7 Hadizadeh DR et al., Proc. Intl. Soc. Mag. Reson. 2010;18:1394