

Clot Lysis Dynamics in an Experimental Rat Venous Thrombosis Model During 4 Weeks of Fibrinolytic Inhibition

Abdel Wahad Bidar¹, Anna Ravnefjord², Frank Risse¹, Edvin Johansson¹, Margareta Elg², and Paul Hockings¹
¹R&D PHB, Imaging, AstraZeneca, Mölndal, Sweden, ²CVGI, Bioscience, AstraZeneca, Mölndal, Sweden

Introduction

Currently, a number of *in vivo*, *ex vivo* models and *in vitro* assays are available to test the efficacy of thrombolytic and fibrinolytic agents. However, these approaches give limited insight into the dynamic process following clot formation and lysis in the same individual. In relevant animal models such knowledge is of interest in order to help understand the mechanism underlying human disease and ultimately to develop novel therapeutic approaches. MRI has previously been shown to be well suited to follow thrombus formation in the same animal and to evaluate treatment effects [1]. The present study compares clot lysis dynamics in a rat model of venous thrombosis with and without treatment with tranexamic acid, a fibrinolytic inhibitor.

Material and Methods

The study was performed in two groups of male Sprague Dawley rats consisting of a control group (n=20) and a treatment group (n=15) given tranexamic acid (Cyklokapron, Pfizer), which inhibits fibrinolysis by blocking the lysine-binding sites of plasminogen to fibrin [2]. Tranexamic acid was administered per oral twice daily (1,000 µmol/kg/day) with the first dose 15 minutes post thrombus induction.

Animals were imaged at days 0, 4, 8 and 12. Additional imaging sessions were performed at days 16, 21 and up to day 28 in animals showing the presence of a persistent clot. At day 0 rats were anaesthetized using isoflurane and thrombosis induced in the abdominal caval vein with topical application of ferric chloride as described previously [3]. Images were acquired on a 9.4T/20 USR Bruker BioSpec with a self-gated FLASH sequence, TR/TE 200/2 ms, FA 25°, NEX 20, FOV 50x50 mm, matrix 256x256 and 30 axial 1 mm thick slices from the inferior caval vein bifurcation to the left renal vein. On day 0 animals were imaged at 40 min post thrombus induction. The thrombus was segmented in each slice using an in-house semi-manual segmentation procedure yielding thrombus volume estimates.

For each experimental animal an estimate of the % remaining thrombus volume over time compared to day 4 (RTV₄) was calculated using the following expression: $\% RTV_4(t) = 100 \times \frac{\text{volume}(t)}{\text{volume}(\text{day } 4)}$. For each individual, the RTV₄ time series was fitted to a mono exponential function and the time T₅₀ at which 50% of the thrombus had lysed was estimated. Statistical comparison of T₅₀ in tranexamic acid treated and control animals were made by a t-test at a 0.05 significance level. Results are expressed as mean ±SEM.

Results

Following thrombus induction, this animal model showed a wide range of clot sizes (8 to 165 µl at day 0). In the initial phase, between day 0 and day 4, additional thrombus growth was in many cases observed in both the treated group and in the control group. Fig. 1 shows axial and reconstructed coronal images of venous thrombi in the abdominal vena cava in the same treated animal at days 4 and 21. A plot representing the mean % RTV₄ as a function of time is presented in Fig. 2. The clot lysed more slowly in the tranexamic acid treated group than in the control group (T₅₀ = 8.4±1.0 versus 4.0±1.5 days, P < 0.05).

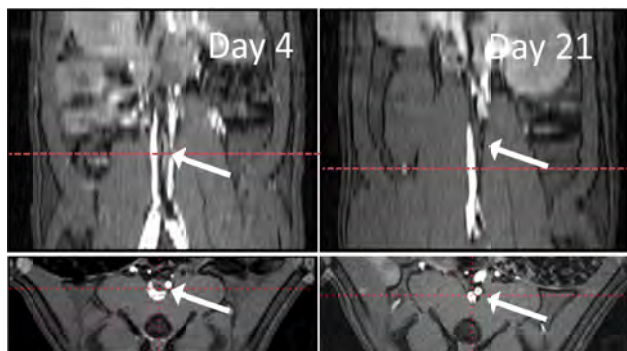


Fig. 1: Sequential coronal and axial images of venous thrombi (arrows) at day 4 and day 21 from a tranexamic acid treated animal.

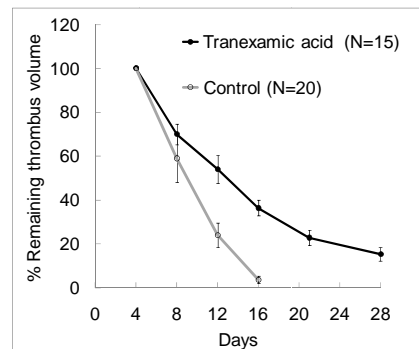


Fig. 2: Mean % remaining thrombus volume as a function of time in control and treated group.

Discussion

The results demonstrated that MRI can be used to follow the long term time course of thrombus lysis. The increase in clot size from day 0 to day 4 shows additional thrombus formation after the first imaging time point. Hence lysis was only analyzed starting from day 4 after which the thrombus volume decayed exponentially. The results demonstrate for the first time the dynamics of clot lysis *in vivo* in rats in the presence of an antifibrinolytic agent. Delayed thrombus lysis rate was measured in tranexamic acid treated animals compared to controls. A non-invasive technique, such as imaging, was useful to remove the confounding effect of a varying initial clot size. This model could be useful for translation between *in vitro* and *in vivo* results and for bridging to clinical results when evaluating thrombolytic and fibrinolytic agents.

References

- [1] Bidar A. et al. Early thrombus development in rats using non-enhanced MRI. Proceedings 17th scientific meeting, ISMRM 2009;17:604.
- [2] Risberg B. Effect of tranexamic acid on pulmonary tissue fibrinolysis in the rat. *Microvas Res* 1976;11:307-314.
- [3] Carlsson S., Elg M. The effects of ximelagatran and warfarin on the prophylaxis of a caval vein thrombosis and bleeding in the anaesthetized rat. *Blood Coagulation & Fibrinolysis* 2005;16(4):245-9.