

# Detection of Carotid Intraplaque Hemorrhage by In Vivo Black Blood Imaging Using Spatial Labeling with Multiple Inversion Pulses Prepared Spoiled Gradient Recalled Sequence

Qingjun Wang<sup>1</sup>, Yong Guo<sup>2</sup>, Jianming Cai<sup>3</sup>, and Minghua Huang<sup>4</sup>

<sup>1</sup>Department of Radiology, Chinese Navy General Hospital, Beijing, Beijing, China, People's Republic of, <sup>2</sup>Department of Radiology, Chinese Navy General Hospital, China, People's Republic of, <sup>3</sup>Chinese PLA General Hospital, <sup>4</sup>Chinese Navy General Hospital

## INTRODUCTION:

Black blood imaging can be used to identify and characterize carotid plaque. Recently, a new black blood imaging based on Spatial LabEling with multiple invErsion pulses prepared SPoiled GRadient Recalled sequence (SLEEK-SPGR) was described and was thought to be more sensitive to detect carotid intraplaque hemorrhage (IPH) compared with conventional three-dimensional time-of-flight (3D-TOF) sequence and inversion recovery (IR) prepared fast spin echo (FSE) sequence [1]. To test this hypothesis, in comparison with excised human specimens from carotid endarterectomy (CEA) we determined whether the SLEEK-SPGR has superiority over 3D-TOF and quadruple inversion recovery (QIR) in detecting carotid IPH.

## MATERIALS AND METHODS:

Between February 2010 and August 2011, we consecutively studied 17 patients (15 men, 2 women,  $69.4 \pm 7.9$  years), who were scheduled for CEA due to cerebrovascular ischemic events (stroke, transient ischemic attack, or amaurosis fugax) in the territory of atherosclerotic carotid stenosis (involving 18 arteries). The axial 3D-TOF, QIR and SLEEK-SPGR were prospectively performed for all these patients within 1 week prior to CEA. All MRI examinations were performed using a 3.0-Tesla (3.0T) MRI scanner (EXCITE HD, GE Healthcare, Milwaukee) and a bilateral 4-channel phased-array surface coil was used. A large coverage axial three-dimensional time-of-flight (3D-TOF) was first performed in order to detect the level of carotid bifurcation. Centered carotid bifurcation, QIR and SLEEK-SPGR were acquired. The images of SLEEK-SPGR were obtained with the following parameters: TR/TE/TI = 9.1/3.5/650 ms, Flip angle =  $10^\circ$ , and a post wait period 800ms after the SPGR acquisition. For the three sequences, slice thickness, field-of-view (FOV) and matrix were the same: 2 mm, 14 cm x 14 cm and 256 x 256. The total scan time was around 15 minutes. Two radiologists evaluated carotid IPH qualitatively (diagnostic accuracy and extent) and quantitatively (lesion-to-plaque ratio, contrast-to-noise ratio) by consensus on 3D-TOF, QIR and SLEEK-SPGR images. Then, differences of the three sequences in detecting IPH were assessed in comparison with matched histological sections of excised specimens.

## RESULTS:

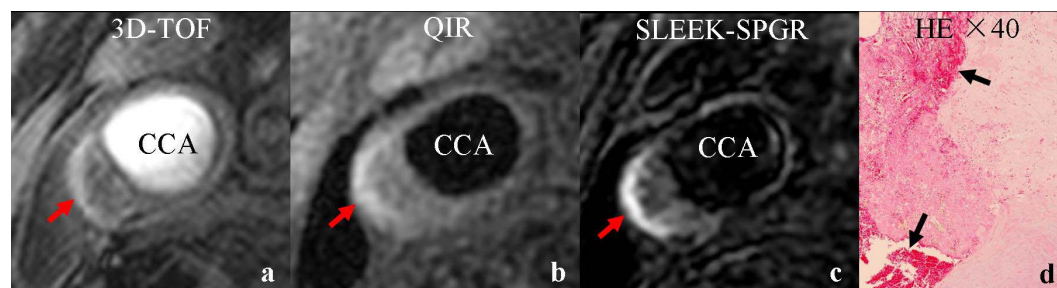
Compared with the corresponding histological specimens, SLEEK-SPGR ( $\kappa=0.91$ ) had a better consistency in defining the extent of carotid IPH than 3D-TOF ( $\kappa=0.73$ ) and QIR ( $\kappa=0.64$ ). SLEEK-SPGR showed a better performance in detecting carotid IPH with higher sensitivity (96.8%) and specificity (85.9%) than 3D-TOF (82.5% and 74.3%) and QIR (75.5% and 72.6%). Quantitative assessment similarly revealed a significant preference for SLEEK-SPGR over 3D-TOF and QIR in lesion-to-plaque ratio ( $P<0.001$ ), contrast-to-noise ratio ( $P<0.001$ ) (Figure).

## DISCUSSION & CONCLUSION:

The superiority of SLEEK-SPGR in imaging IPH is attributable to the two inversion recovery (IR) pulses, which added to a 3D segmented SPGR sequence. The first IR pulse with a broad spatial band is designed to saturate the blood flow and the second IR pulse with narrower spatial band is to recover the wanted signal from the imaging volume. TI is selected to null the blood signal. As a result, the IPH with a short T1 relaxivity value is highlighted. Our findings confirmed that SLEEK-SPGR has very higher sensitivity and specificity in detecting carotid IPH, and can provide a better visualization of carotid IPH than traditional 3D-TOF and QIR images.

## REFERENCES:

[1]. H. Shen et al. The 18<sup>th</sup> ISMRM Annual Meeting & Exhibition 2010.



**Figure** Right atherosclerotic common carotid artery with IPH. 3D-TOF (Fig. a) and QIR (Fig. b) showed high signal intensity in plaque (IPH, red arrows). However, the IPH presented as stronger signal intensity on SLEEK-SPGR (Fig. c, red arrow). Hematoxylin-eosin staining section with 40 times magnification confirmed the IPH (Fig. d, black arrows).