

## ADC mapping for carotid plaque characterisation

Victoria Young<sup>1</sup>, Andrew J Patterson<sup>2</sup>, Umar Sadat<sup>3</sup>, Andrew N Priest<sup>2</sup>, Robert van de Geest<sup>4</sup>, Martin J Graves<sup>1,2</sup>, and Jonathan H Gillard<sup>1</sup>

<sup>1</sup>Radiology, Addenbrooke's Hospital, Cambridge, Cambridgeshire, United Kingdom, <sup>2</sup>Medical Physics and Engineering, Addenbrooke's Hospital, Cambridge, United Kingdom, <sup>3</sup>Vascular Surgery, Addenbrooke's Hospital, Cambridge, Cambridgeshire, United Kingdom, <sup>4</sup>Radiology, Leiden University Medical Center, Leiden, Netherlands

### Background and Purpose

Multi-contrast magnetic resonance imaging (HR-MRI) has previously been used to identify both degree of stenosis and plaque morphology for carotid atheroma [1, 2]. Previous studies applying conventional spin echo diffusion-weighted imaging (DWI) to ex-vivo carotid specimens have reported that DWI improved classification of plaque components [3]. Apparent diffusion coefficient (ADC) maps have been used to demonstrate different ADC values in lipid core and fibrous cap tissue in vivo [4] and ex vivo [5]. A small ex vivo study of femoral atheroma has also suggested that aging thrombus may demonstrate different ADC characteristics. The aim of this study was to examine if the plaque classification using DWI through ADC mapping can be expanded to include thrombus and that the previous demonstrated differences between lipid core and fibrous tissue.

### Materials and Methods

93 patients (64 males) with confirmed carotid stenosis on Doppler ultrasound were recruited and imaged on at 1.5T (Signa HDx, GE Healthcare, Waukesha, WI) using a bilateral four-channel phased-array carotid coil (PACC, Machnet BV, Eelde, The Netherlands). Multi-contrast images were obtained over the stenotic section of the artery using cardiac-gated, fat suppressed double inversion recovery fast spin echo sequences (T<sub>1</sub>W, T<sub>2</sub>W, PDW and STIR). A previously published single shot diffusion weighted echo planar imaging sequence without cardiac gating was used to obtain diffusion-weighted images [4]. Imaging parameters were: FOV 16x8cm; Matrix 128x128; NEX 16; TR 2200ms; TE 75ms; slice thickness 3mm; b value 0/500s/mm<sup>2</sup>; and in-plane resolution 1.25mm. Spatial saturation bands were applied superiorly/inferiorly (blood signal suppression) and anteriorly/posteriorly (phase wrapping artefact minimisation). Diffusion gradients were applied in the x, y and z axes and apparent diffusion coefficient (ADC) maps were computed.

The multi-contrast images were segmented using a semi-automated method to identify the vessel wall, lumen and plaque components (Vesselmass, Leiden University Medical Centre, Leiden, The Netherlands). The ROIs identified as thrombus were further sub-classified into fresh, recent and old using previously published criteria [6]. The regions of interest (ROIs) were then transferred onto the ADC maps and the mean ADC value for each ROI was recorded. ADC values for LR/NC, fibrous cap (automatically generated), thrombus and fibrous tissue were compared using a linear mixed effect model ( $P < 0.05$  was considered significant). ROIs for calcification were excluded as this component should not demonstrate diffusion.

### Results

Of the 93 patients recruited, all had imaging suitable for analysis with a stenosis range of 40-84%. Of the 93 patients analysed 55% were symptomatic. A total of 461 diseased slice locations were analyzed (median = 4, range 2-12 per patient). A total of 123 arterial locations demonstrated lipid core, all fibrous tissue, 73 fibrous cap, 136 thrombus and 49 calcification. Thrombus was further sub-classified with 39 containing fresh thrombus, 50 recent thrombus, 19 old thrombus and 24 mixed thrombus (more than one category on the same slice).

There was a significant difference in ADC values between the delineated fibrous tissue, lipid core and thrombus regions (figure 1). Fresh thrombus demonstrated a different ADC value from the other thrombus types. Fibrous cap and fibrous tissue had similar mean ADC values. The mean ADC values for the components at a patient level are given in table 1.

### Discussion

Previous work in vivo and ex vivo demonstrated the ability of ADC mapping to distinguish lipid rich necrotic core from fibrous tissue [4, 5]. This study shows that this finding can still be demonstrated on a larger population with a broad range of stenosis. ADC mapping can be expanded to distinguish thrombus from lipid core as well which aids in the delineation of another feature of plaque risk. Sub-classification of thrombus has illustrated that there is variation in the ADC value for different types of haemorrhage (figure 2) with fresh haemorrhage being significantly different. This is important to define because age of haemorrhage has been shown to relate to symptomatology and plaque biomechanics [7, 8] and in turn to subsequent events [9]. Fibrous cap demonstrated a similar ADC value to fibrous tissue as would be expected, but with a broader range that may represent the variable condition of the fibrous cap, from thick, to thin and ruptured.

The advantages of DWI through ADC mapping are that it provides a quantitative assessment method that as a whole differentiates the three major plaque components without the use of contrast media which may benefit the role of unenhanced carotid imaging. One limitation is the lack of histological confirmation of the plaque characterisation – multicontrast MRI was used as the standard. However, histological confirmation is not available for lower degrees of stenosis which formed part of the patient population.

### Conclusion

This in vivo study indicates that ADC mapping can be used to distinguish the three key plaque components as well as providing information on thrombus age; this may provide additional benefit in delineation of plaque morphology.

### References

1. Trivedi, R.A., et al., *Neuroradiology*, 2004. 46(9): p. 738-43.
2. Yuan, C., et al., *Circulation*, 1998. 98(24): p. 2666-71.
3. Clarke, S.E., et al., *Magn Reson Med*, 2003. 50(6): p. 1199-208.
4. Young, V.E., et al., *Neuroradiology*, 2010. 52(10): p. 929-36.
5. Qiao, Y., et al., *Arterioscler Thromb Vasc Biol*, 2007. 27(6): p. 1440-6.
6. Chu, B., et al., *Stroke*, 2004. 35(5): p. 1079-84.
7. Sadat, U., et al., *Atherosclerosis*, 2009. 207(2): p. 434-9.
8. Sadat, U., et al., *Int J Cardiovasc Imaging*, 2010.
9. Sadat, U., et al., *Eur J Vasc Endovasc Surg*, 2010. 40(4): p. 485-91.

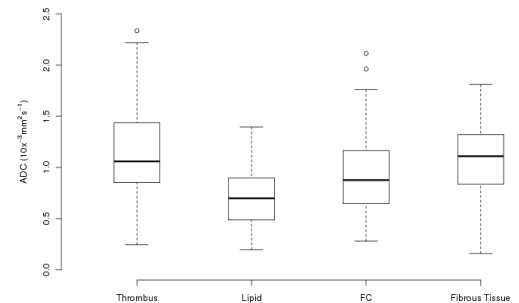


Figure 1: ADC values of the individual plaque components at a patient level

Component	Mean [standard deviation] ( $\times 10^{-3} \text{ mm}^2/\text{s}$ )
Fibrous tissue	1.09 [0.34]
Lipid core	0.71 [0.30]
Fibrous cap	0.98 [0.45]
Thrombus	1.23 [0.64]
Fresh	1.47 [0.71]
Recent	1.01 [0.31]
Old	0.85 [0.50]
Mixed	0.89 [0.56]

Table 1: Mean ADC values of plaque components

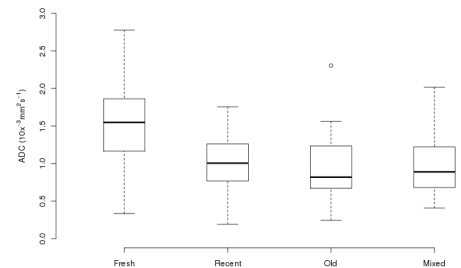


Figure 2: ADC values of different plaque thrombus types at a patient level