

THE EFFECT OF LEFT BUNDLE BRANCH BLOCK AND HEART FAILURE ON CIRCUMFERENTIAL RIGHT VENTRICULAR DYSSYNCHRONY AND FUNCTION: ASSESSMENT WITH MR CINE DENSE

Daniel A. Auger¹, Bruce S. Spottiswoode^{1,2}, Loren P. Budge³, Xiaodong Zhong⁴, Frederick H. Epstein⁵, and Kenneth C. Bilchick³
¹MRC/UCT Medical Imaging Research Unit, University of Cape Town, Cape Town, Western Cape, South Africa, ²Division of Radiology, University of Stellenbosch, Cape Town, Western Cape, South Africa, ³Department of Medicine/Cardiovascular Division, University of Virginia, Charlottesville, Virginia, United States, ⁴MR R&D Collaborations, Siemens Healthcare, Atlanta, Georgia, United States, ⁵Departments of Radiology and Biomedical Engineering, University of Virginia, Charlottesville, Virginia, United States

Introduction: The overall benefit of cardiac resynchronization therapy (CRT) to selected patients with heart failure (HF) has been shown in clinical trials, but the nonresponse rate to CRT using current clinical indications is still significant at approximately 30-40% (Circulation 2008; 117:2608-16). In addition to left ventricular (LV) dyssynchrony, right ventricular (RV) dyssynchrony and dysfunction may be an important determinant of clinical CRT response; however, quantitative assessment of dyssynchrony in the thin-walled RV is challenging with echocardiography and even with MR myocardial tagging. MR cine displacement encoding with stimulated echoes (DENSE) offers high resolution strain encoding into the phase of the MR signal and may be the optimal method to assess RV dyssynchrony.

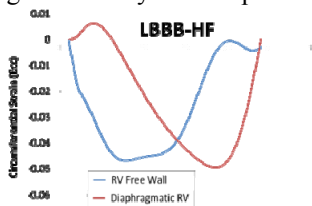


Figure 1: Regional Ecc in LBBB-HF

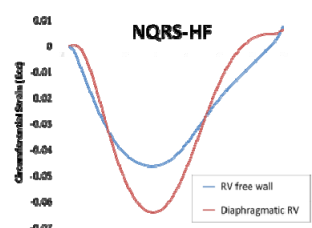


Figure 2: Regional Ecc in NQRS-HF

Methods: Using a 1.5T Avanto scanner (Siemens Medical Solutions) with a 4-channel phased-array chest radiofrequency coil, we performed cine DENSE imaging (MRM 2010; 64:1089-97) in standard short-axis planes in two orthogonal directions in n=12 canines: 4 with HF and a normal (narrow) QRS (NQRS-HF), 4 with HF and left bundle branch block (LBBB) induced by catheter ablation (LBBB-HF), and 4 normal controls. Scan parameters were: interleaved spiral readout with 6 interleaves per image; repetition time(TR)/echo time(TE) 17ms/1.9ms; section thickness 8 mm; field of view 350 x 350 mm; flip angle 15°; pixel size 2.8 x 2.8 mm; echo spacing 17 ms with view sharing; and displacement-encoding frequency 0.1 cycles/mm. Circumferential strain (Ecc) was determined from the DENSE data for the RV free wall (RVFW) and diaphragmatic RV (DRV) based on mid-cavity short-axis RV/LV slices using custom software. Volumetric assessments were performed using standard software. The protocol was approved by the University of Virginia Animal Care and Use Committee.

Results: Animals with HF had reduced LVEF and increased LVEDV compared with controls (LVEF: median[IQR] 0.13 [0.11,0.21] v. 0.51 [0.44,0.58], p<0.01; LVEDV: 82cc [75cc,105cc] v. 65cc [61cc,73cc], p=0.03). Increases in LVEDV associated with HF were more prominent than the observed increases in RVEDV associated with HF.

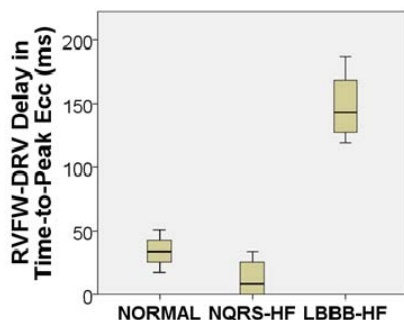


Figure 3: RV Dyssynchrony by Group

LBBB-HF animals had more LV circumferential dyssynchrony than NQRS-HF or control animals based on the circumferential uniformity ratio estimate parameter (CURE, range 0-1, 0=dyssynchrony, 1=synchrony) (0.43 [0.24,0.54] v. 0.97 [0.95,0.98] v. 0.96 [0.96,0.99], p<0.01). RVFW peak Ecc was similarly depressed in the LBBB-HF and NQRS-HF animals compared with controls (-0.07 [-0.12,-0.03] v. -0.08 [-0.11,-0.05] v. -0.14 [-0.19,-0.10], p=0.09 [trend] for HF v. controls). Peak contraction (Ecc) was markedly delayed in the DRV relative to the RVFW in LBBB-HF animals (example, Figure 1) compared with NQRS-HF (example, Figure 2) and control animals (143ms [128ms,169ms] v. 8.5ms [0ms,26ms] v. 34 ms [26ms,43ms], p<0.03 for both comparisons) (Figure 3).

Conclusions: MR Cine DENSE provides RV strain with high spatio-temporal resolution and facilitates determination of RV dyssynchrony. Chronic heart failure with LBBB results in significant delays in contraction of the diaphragmatic RV relative to the RV free wall. RV dyssynchrony assessed in this way may be an important determinant of CRT response and merits further clinical evaluation.