

A COMPARATIVE STUDY OF RCBF MAPS WITH ARTERIAL SPIN LABELING AND FDG-PET IN DEMENTIA AND ALZHEIMER'S DISEASE

Pablo García-Polo García¹, Juan Antonio Hernández-Tamames², Roberto García-Álvarez³, Eva Alfayate⁴, and Juan Álvarez-Linera⁵

¹Neuroimaging Lab., Centre for Biomedical Imaging, Pozuelo de Alarcón, Madrid, Spain, ²Universidad Rey Juan Carlos, Móstoles, Madrid, Spain, ³Research and Collaborations Department, GE Healthcare, Buc, France, ⁴Cien Foundation - Centre for Alzheimer's Disease Queen Sofia Foundation, Madrid, Spain, ⁵Hospital Ruber Internacional, Madrid, Spain

Introduction

Arterial Spin Labeling is a non-invasive MRI technique, which allows the quantification of regional cerebral blood flow (rCBF) without contrast agents. In contrast, Positron Emission Tomography with FDG (FDG-PET) is considered the gold standard for mapping brain metabolism and task-induced brain activity in normal and pathologic states. In this work, we have focused on Alzheimer's disease (AD) that is the most common cause of dementia. Prior studies with ¹⁵O-water PET and FDG-PET have shown an important decrease of perfusion in regional Cerebral Blood Flow (rCBF) maps and cerebral metabolic rate of glucose in regions such as parietal lobes and posterior cingulate [1,2]. This work will assess the correlation between these two techniques and the feasibility of ASL as a near-future substitute of FDG-PET in the study of dementia.

Experimental Methods

ASL allows the measurement of rCBF maps by labeling a small bolus of blood at the level of the carotid arteries with a radiofrequency pulse [Fig1]. This technique has shown its validity in measuring perfusion in neurodegenerative diseases [1]. Initially, the agreement between ASL and FDG-PET was assessed in a group of 24 subjects, classified into 3 subgroups: 5 young subjects with a mean age of 26.7 ± 13.4 years, 10 elder subjects with a mean age of 73.2 ± 6.7 years and 9 AD patients with a mean age of 69.9 ± 9.5 years.

In the second part of this study only ASL was performed on a mixed group of 99 subjects divided in 4 subgroups: 33 healthy control (72.7 ± 5.9 y), 22 aMCI (74 ± 6.2 y), 22 mMCI (75.9 ± 5.1 y) and 22AD (76.5 ± 8.2 y) paired by gender. All subjects and patients participating in this study received prior informed consent per guidelines of the institutional review board.

FDG-PET data were acquired with a GE Discovery STE PET machine using a 128×128 acquisition matrix, 47 slices, with $2 \times 2 \times 3.27$ mm voxel resolution and a 3D-IR reconstruction method. All MR imaging was performed on a 3T Signa HDx MR scanner (GE Healthcare, Waukesha, WI) using an eight-channel phased array coil. A 3D PCASL pulse sequence with a matrix size= 128×128 , resolution= $2.3 \times 2.3 \times 4$ mm, flip angle = 155° , transit time= 1.5 s, TR= 9.34 s and a TE= 1.9 ms was used to generate the rCBF maps.

Corregistration, normalization and smoothing (FWHM=4mm) of ASL-rCBF and FDG-PET maps were performed with Statistical Parametric Map (SPM8) software. Various statistical maps, using a Multiple Regression Analysis within the General Linear Model, were then obtained.

Results

Figure 2 displays the MNI ch2bet brain template, where highlighted color-coded areas correspond to the differences ($p < 0.001$) between the Control, young and elder, and AD patient subgroups for both ASL (top row) and FDG-PET (bottom row). Highlighted regions shown in Figure 2a, 2c and 2e reveal areas of hypoperfusion in the AD patients, while those on Figs. 2b, 2d and 2f are indicative of decreased metabolism. The hypoperfusion patterns for both comparisons are found to be highly similar for both techniques. No significant differences between young and elder controls ($p < 0.001$) were found.

Figure 3 shows the results of the comparison ($p < 0.005$) between Controls and aMCI (Fig. 3a), mMCI (Fig. 3b) and AD (Fig. 3c). Important perfusion deficits in aMCI, mMCI and AD were found in posterior cingulate.

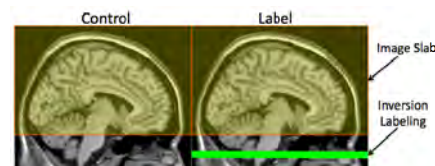

Figure 1 ASL acquisition scheme

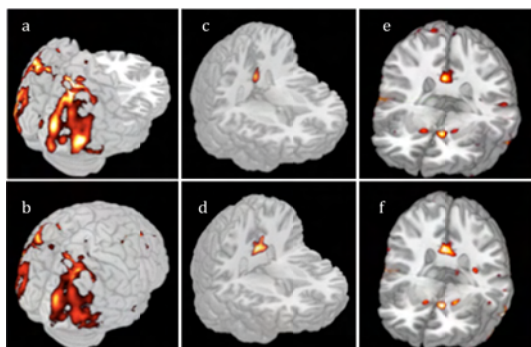


Figure 2 SPM8 Probabilistic maps co-registered to brain template. Columns left-to-right show rotated brain around a superior-inferior axis at 3 identical positions. Top and bottom rows show different between healthy and AD for ASL and PET respectively

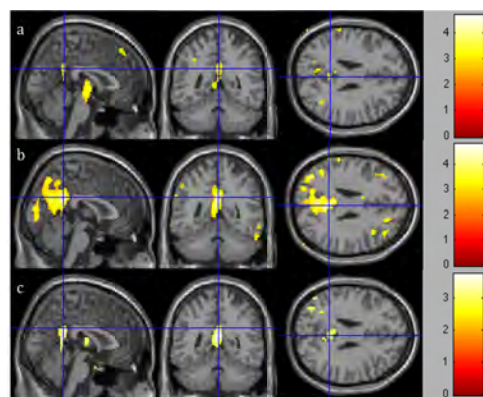


Figure 3 SPM8 Probabilistic maps after the comparison between Controls and aMCI (row a), mMCI (row b) and AD (row c)

Conclusions

The results reveal that cerebral blood flow and metabolism in healthy subjects does not decline significantly with age. Thus, in the absence of significant medical conditions and a large loss of grey matter, resting cortical perfusion may be unaltered. In AD patients, the brain regions that were observed to have a significantly decreased perfusion and metabolism in grey matter were the posterior cingulate and posterior lobes, as seen in other studies [1,2]. The second part of this study, where only ASL was utilized, revealed important decreased perfusion in posterior cingulate in patients with AD. This observation was made following a comparison of the controls and early stage of AD patients (i.e. aMCI and mMCI). This body of work demonstrates the capability of ASL as a promising technique to monitor the AD and other dementias.

References

- [1] Assessment of cerebral blood flow in Alzheimer's disease by spin-labeled magnetic resonance Imaging, D. C. Alsop, et al., Annals of Neurology, Jan 2000, Volume 47, 1, p.93-100
- [2] Normal and pathological aging: findings of positron-emission-tomography. Mielke R., et al., J Neural Transm 1998; 105:821-837.