

Age-Related Changes of Bone Marrow in the Mandible with Quantitative MRI

Kotaro Sekiya^{1,2}, Osamu Sakai¹, Memi Watanabe¹, Rohini N. Nadgir¹, Joseph H. Liao¹, Shun Sakai¹, Takashi Kaneda³, and Hernan Jara¹

¹Boston Medical Center, Boston University School of Medicine, Boston, MA, United States, ²Nihon University Graduate School of Dentistry at Matsudo, Matsudo, Chiba, Japan, ³Department of Radiology, Nihon University School of Dentistry at Matsudo, Matsudo, Chiba, Japan

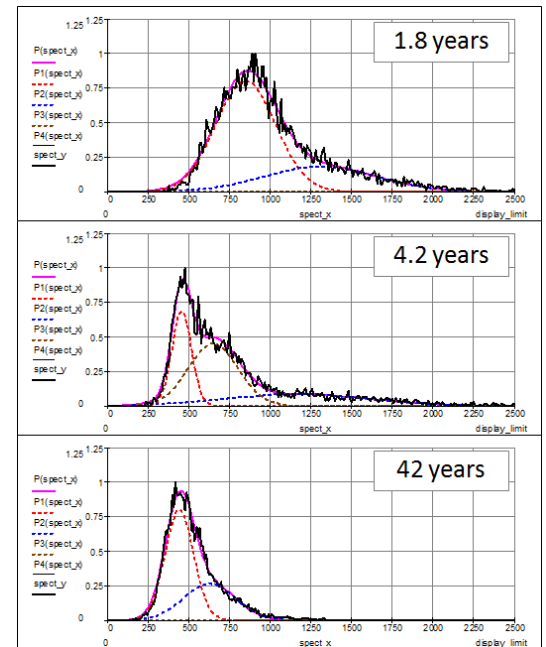
Introduction: The expected age-related change from red to yellow marrow has been described qualitatively by MR imaging (Ref. 1-2). To our knowledge, multi-spectral quantitative magnetic resonance imaging (qMRI) analysis of age-related change of the mandibular marrow has not been reported.

Purpose: To determine the normal T1 and T2 relaxo-volumetric aging patterns of the mandible using multi-spectral qMRI, both globally and regionally, and covering an age range approaching the full human lifespan.

Materials and Methods: Following IRB approval, 36 subjects (18 males, 18 females, age range of 0.5-87 years) were enrolled for this study. Study population consisted of 2 volunteers and 34 patients who underwent brain MRI for various clinical indications. No subject carried a history of hematological disorder or malignancy. In addition to routine clinical brain imaging, all subjects were imaged with the mixed-TSE pulse sequence with a 1.5T MR scanner (Intera or Achieva, Philips Medical Systems, Cleveland, OH). The mandible was manually segmented using 3D slicer 2.6, and further divided into 5 sub-segments; (I) anterior region, (II) premolar/molar region, (III) angle, (IV) ramus, and (V) condyle. The data sets were analyzed using a previously described technique (Ref. 3-4) that provides self-registered and volumetric qMRI data sets. T1 and T2 histograms were generated with a pixel counting algorithm and further modeled with Gaussian functions. Peak values were derived from the histograms and plotted as a function of age.

Results: Histograms of the mandible demonstrated expected age-related changes in bone marrow components. Examples of T1 histograms of selected subjects are shown in Fig. T1 histograms of the whole mandible were primarily bimodal, but differed in shape and peak location depending on age. In children age 0-4 years, T1 histograms consisted of a small broad peak at around 1400ms and a large peak with lower T1 values, suggestive of tooth follicles and red marrow, respectively. A separate peak of yellow marrow was demonstrated at around 450ms in subjects older than 4 years old, resulting to three distinct peaks in children age 4-10 years old. T1 histograms revealed a transition stage between age 4 years and early 20s. Finally, in adult subjects over 30 years old, T1 histogram showed a large peak of yellow marrow and also demonstrated a small peak at higher T1 values, which was suggestive of non-marrow components, such as the neurovascular bundle within the mandibular canal. These age-related changes in marrow components were also demonstrated in T2 histograms. T1 histograms of each sub-segment were similar to those of the whole mandible, with the exception of tooth follicle components in region I, II and III in younger subjects. However, the temporal progression of marrow change to complete adult-type marrow was region-specific, with most delayed maturation seen in region V. The peak values of yellow marrow were relatively consistent and independent of age and location, while the peak of other tissues including red marrow showed a decline with age in each region. The ratios of mandibular volume to intracranial volume were smaller (0.01-0.02) during childhood, remained relatively consistent at around 0.03-0.04 during adulthood, and showed smaller ratio in some of the older subjects.

Conclusion: Expected progression of marrow change in the mandible by visual estimates is confirmed quantitatively in this investigation; such quantitative analysis may ultimately prove useful in detecting subtle marrow abnormalities prior to becoming visually apparent.



References:

1. Kaneda T, Minami M, Ozawa K, et al. Magnetic resonance appearance of bone marrow in the mandible at different ages. *Oral Surg Oral Med Oral Pathol Oral Radiol Endod* 1996;82(2):229-233.
2. Yamada M, Matsuzaka T, Uetani M, Hayashi K, Tsuji Y, Nakamura T. Normal age-related conversion of bone marrow in the mandible: MR imaging findings. *AJR Am J Roentgenol* 1995;165(5):1223-1228.
3. Suzuki S, Sakai O, Jara H. Combined volumetric T1, T2 and secular-T2 quantitative MRI of the brain: age-related global changes (preliminary results). *Magn Reson Imaging* 2006;24:877-887
4. Saito N, Sakai O, Ozonoff A, et al. Relaxo-volumetric multispectral quantitative magnetic resonance imaging of the brain over the human lifespan: global and regional aging patterns. *Magn Reson Imaging* 2009;27:895-906