

Functional connectivity analysis reveals disrupted interhemispheric connectivity in unilateral neocortical epilepsy

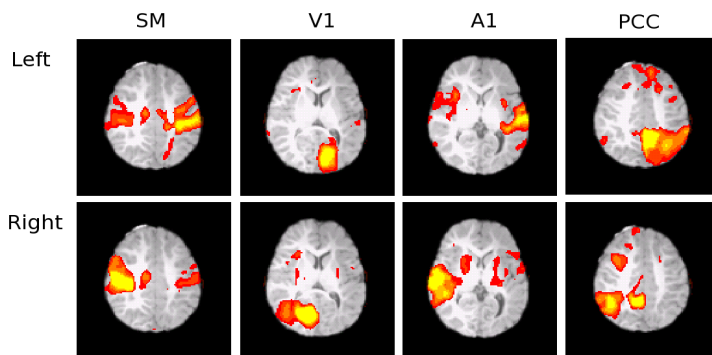
Edward J Novotny^{1,2}, Andrew Poliakov³, Sandra Poliachik³, Seth Friedman³, Dennis Shaw³, and Jeffrey Ojemann^{1,4}

¹Pediatrics, University of Washington, Seattle, WA, United States, ²Neurology, University of Washington, Seattle, WA, United States, ³Radiology, Seattle Children's Hospital, Seattle, WA, United States, ⁴Neurosurgery, University of Washington, Seattle, WA

Introduction: Functional connectivity MRI (fcMRI) – an analysis technique based on task-free, resting state fMRI recording -- can demonstrate disruption of connectivity in certain disease states, including epilepsy. In healthy controls, fcMRI reveals strong interhemispheric connectivity in such systems as sensory-motor, visual, auditory, as well as dorsal attention and default mode networks. We applied this technique to several patients with intractable epilepsy being considered for surgical resection due to unilateral involvement of the disorder in such conditions that include Sturge-Weber, Rasmussen syndrome, peri-natal cerebral infarct and malformations of cortical development.

Methods: Seventeen subjects with medically intractable epilepsy being considered for epilepsy surgery were studied using fcMRI as part of a comprehensive epilepsy evaluation that included high-resolution anatomical MRI at 3T, FDG-PET, video/EEG monitoring with ictal recordings, Neuropsychological and developmental testing. There were 5 male subjects and the mean age was 7 years with the age range from 0.1 to 18 years. The imaging was performed on a Siemens (Erlangen, Germany) system, 3-Tesla (Trio) scanner with the following sequence (EPIBOLD sequence, TE=30ms, flip angle = 90°). Resting state fMRI scan were performed in both awake and anesthetized patients. The fcMRI study was incorporated into either clinical anatomical MRI or task-based fMRI studies that were part of their routine presurgical evaluation. Awake patients were instructed to relax and rest while keeping their eyes open. Analysis was performed using 1000 Functional Connectomes Project scripts based on AFNI and FSL software packages. Resting state data were analyzed for connectivity with the following seeds: Somatomotor (MNI coordinates: $(\pm 39, -27, 51)$); Visual V1($\pm 18, -72, 12$); Auditory A1($\pm 60, -12, 0$); Default Mode/posterior cingulate cortex PCC($\pm 6, -48, 39$). In patients with anatomical anomalies, the location of the fixed coordinate was confirmed to be on the appropriate brain region by a clinical neuroscience physician.

Results: All subjects with epilepsy had significant disruptions in functional connectivity involving one or more resting state networks. These changes included marked asymmetries of networks, impairment of interhemispheric connectivity and aberrant patterns of activation when compared to controls without epilepsy.



The figure shows connectivity patterns in a 2 y/o patient with left hemisphere cortical dysplasia. While some interhemispheric connectivity remained in somatomotor (SM) and auditory (A1) systems, it was disrupted in Visual (V1) and default mode (PCC) networks.

Conclusions: Resting state functional connectivity patterns are well documented in healthy subjects. In patients with epilepsy, such data is limited and has only recently been applied to patients being considered for epilepsy surgery (1,2) and other epilepsy syndromes.

References:

1. Negishi M, Martuzzi R, Novotny EJ, Spencer DD, Constable RT. Functional MRI connectivity as a predictor of the surgical outcome of epilepsy. *Epilepsia*. 52(9):1733-40, 2011.
2. Bettus G, Ranjeva JP, Wendling F, Bénar CG, Confort-Gouny S, Régis J, Chauvel P, Cozzone PJ, Lemieux L, Bartolomei F, Guye M. Interictal functional connectivity of human epileptic networks assessed by intracerebral EEG and BOLD signal fluctuations. *PLoS One*. 2011;6(5):e20071.

We studied a number of such patients, and found that interhemispheric connectivity is clearly disrupted. This can be either limited to select systems or show broad disconnect between the two hemispheres. We may see broadening of connectivity in the diseased area. This disruption of interhemispheric connectivity happens despite intact callosal connections and suggests mechanisms beyond simple structural connections are necessary to drive functional networks. These preliminary results show promise for the application of fcMRI to the presurgical evaluation of patients with epilepsy and investigating the relationship of the fcMRI findings to surgical outcome and comorbid neuropsychological dysfunction.