

## Mapping complex white matter structures with d-PFG MRI 3D acquisition scheme

Michal E Komlosh<sup>1,2</sup>, Evren Ozarslan<sup>1,2</sup>, Martin J Lizak<sup>3</sup>, and Peter J Basser<sup>1</sup>

<sup>1</sup>STBB, PPITS, NICHD, NIH, Bethesda, MD, United States, <sup>2</sup>CNRM, USUHS, Bethesda, MD, United States, <sup>3</sup>NMRF, NINDS, NIH, Bethesda, MD, United States

### Introduction:

The diameter of myelinated axons is a key neurophysiological parameter since it is directly proportional to the conduction velocity of action potentials traveling along them. Therefore, knowledge of the axon diameter can help in characterizing neural microstructure in the peripheral and central nervous system as well as in gaining insights into pathologies. To date, several MRI based methods to measure axon diameter have been proposed. AxCaliber MRI<sup>1</sup> uses conventional diffusion weighted imaging (DWI) consisting of a Stejskal-Tanner single pulsed-field gradient (PFG) sequence played out with diffusion gradients applied perpendicular to the axon's axis. This approach is limited to cases in which the direction of the white matter pathways is assumed to be known *a priori*. An alternative approach is to use a double PFG (d-PFG)<sup>2</sup> MR sequence, which entails applying two pair of Stejskal-Tanner diffusion gradient (PFG blocks). Using this approach axon diameter can also be measured by sweeping the orientation of the second gradient vector within the plane perpendicular to the axons' fiber axes. Again, this method can provide estimates of average axon diameter in highly ordered tissues such as fixed spinal cord<sup>3</sup> and corticospinal tract<sup>4</sup> when the orientation of the fascicles is known *a priori*. In this study we generalize this d-PFG MRI experiment to be able to characterize axon diameters lying in any arbitrary orientation using a full 3D d-PFG MRI acquisition<sup>5</sup> and employ a mathematical modeling framework to simultaneously estimate axon's orientation, and its diameter. Here we demonstrate this method in a coronal slice of rat corpus callosum, whose fiber orientation is known to vary within the slice plane.

### Materials and Methods:

Formalin-fixed healthy rat brains were rehydrated and placed in a 7T vertical-bore Bruker BioSpin MRI magnet with a DRX console. D-PFG filtered MRI sequences were applied in which the d-PFG NMR parameters were:  $\delta=3.15\text{ms}$ ,  $\Delta=30\text{ms}$ , and the gradients, whose magnitude ranged between 0 and  $664\text{mT/m}^{-1}$ ; and applied along 69 orientations evenly distributed on a sphere. MRI parameters were: TR/TE = 3500/6.12 ms, FOV=17 mm, resolution= $170\times 170\times 1000\text{ }\mu\text{m}^3$ . In this implementation, the d-PFG NMR block is applied as a filter followed by an MRI sequence. A theoretical framework<sup>6</sup> was used to fit the data, which takes into account the restricted signal within the axons and a possible free water compartment<sup>7</sup>. A pixel-by-pixel analysis was performed to generate a fiber diameter map in the white matter region of interest (ROI) within the rat corpus callosum.

### Results

In Figure 1, the direction-encoded color (DEC) map obtained from DTI shows a clear variation of fiber orientation of the corpus callosum within the slice plane. The DEC map obtained from the analysis of the 3D d-PFG data yielded consistent fiber orientation results. Figure 1b shows the average fiber diameter map calculated from the d-PFG filtered MRI experiments overlaid on a non-diffusion weighted d-PFG image. Fiber diameter estimates ranged between 1 and 3  $\mu\text{m}$  with a mean diameter of 1.5  $\mu\text{m}$ .

### Discussion

The average axon diameter map estimates within the corpus callosum exhibited little variation, which is expected for coronal slice. The computed fiber diameters are in the expected range for the imaged area of the corpus callosum<sup>8</sup>.

### Conclusion

D-PFG filtered MRI is a powerful tool for mapping axon diameter in white matter where the fiber orientation is either unknown or changes within the image plane. Therefore, the technique can be used to simultaneously estimate the orientation and diameter of white matter fibers in the brain.

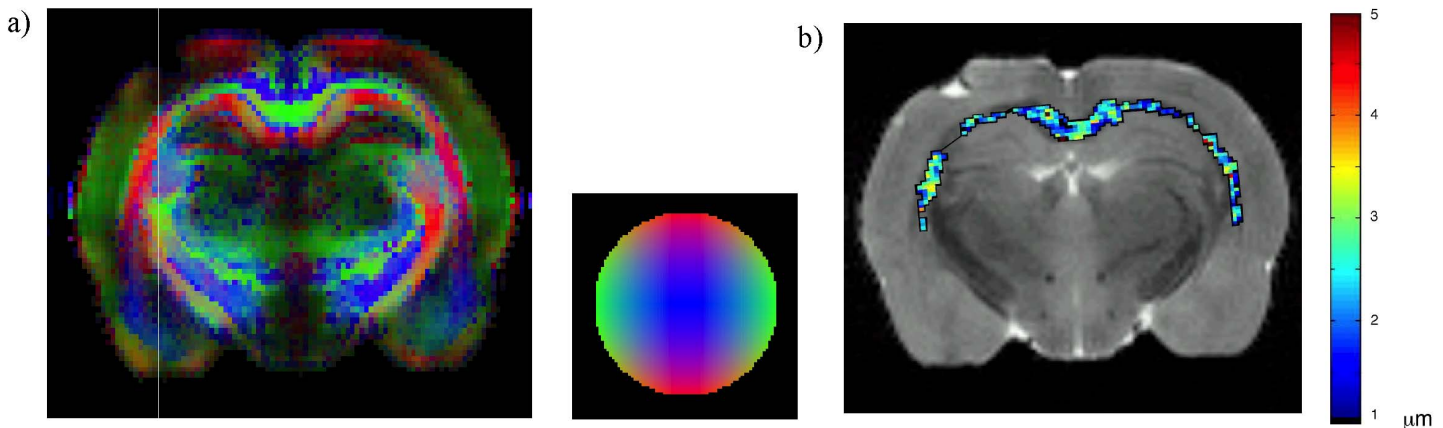


Figure 1. a) Direction-encoded color (DEC) map obtained from an independent DTI acquisition showing the fiber orientation. b) Average fiber diameter map (color) computed from d-PFG filtered MRI experiment overlaid on a non-diffusion weighted d-PFG image (grayscale).

### References:

1. Y. Assaf et al. *Magn Reson Med*, **59**, 1347
2. P.P. Mitra, *Phys. Rev. B* **51**, 15074, (1995)
3. T. Weber, et al. *Magn Reson Med* **61**, 1001, (2009).
4. M. A. Koch, et al. *Proc Intl Magn Reson Med* **16**, 764, (2008).
5. M. E. Komlosh, et al. *J Magn Reson* **208**, 128, (2011).
6. Özarslan et al. *J Chem Phys*, **130**, 104702, (2009).
7. Shemesh et al. *J Magn Reson*, **200**, 214, (2009).
8. D. Barazany *Brain*, **132**, 1210, (2009).