

# The Feasibility of Endorectal MR Elastography for Prostate Imaging in Human Volunteers

Arvin Arani<sup>1,2</sup>, Michael Da Rosa<sup>3</sup>, Elizabeth Ramsay<sup>1</sup>, Donald Plewes<sup>1,2</sup>, Masoom Haider<sup>1</sup>, and Rajiv Chopra<sup>1,2</sup>

<sup>1</sup>Sunnybrook Research Institute, Toronto, Ontario, Canada, <sup>2</sup>Medical Biophysics, University of Toronto, Toronto, Ontario, Canada, <sup>3</sup>Institute of Medical Science, Sunnybrook Research Institute, Toronto, Ontario, Canada

**Introduction:** Multi-parametric magnetic resonance imaging (MPMRI), in combination with an endorectal coil, is increasingly being used to help localize prostate cancer. Stiffness may be an additional parameter that may be beneficial to incorporate into MPMRI since malignant prostate tissue has been reported to be 2-4 times stiffer than healthy tissue. Dynamic shear wave elastography, in particular, gives quantitative stiffness measurements by transmitting micrometer amplitude shear waves into tissues. Previous attempts of measuring prostate stiffness in patients have been limited to using frequencies between 65-100Hz<sup>1,2</sup> due to so the significant attenuation of shear waves by soft tissue. This imposes a limitation on the spatial resolution of the stiffness maps (elastograms). The primary challenge reported by these authors has been to generate sufficient amplitude shear waves inside the prostate using an external actuator. Recently, the feasibility of using an intracavitary actuator for magnetic resonance elastography (MRE) has been proven to be technically feasible in an *in vivo* canine model<sup>3</sup>. The advantage of using an intracavitary actuator over an external actuator is that the necessary penetration depths of these shear waves is reduced from 10-15 cm to 3-5 cm. A shorter penetration depth allows for higher frequency shear waves to be sent into the organ of interest giving an estimated 3 fold increase in the spatial resolution of the technique. It is common practice to use an endorectal coil in MPMRI to improve the signal to noise (SNR). It has been shown previously in phantom experiments<sup>4</sup> that an endorectal coil can serve as a means for generating shear waves in direct proximity to the gland while simultaneously imaging with the coil. *The objectives of this study were to investigate the tolerability and technical feasibility of performing endorectal MRE(eMRE) in human volunteers within the representative age group commonly affected by prostate cancer.*

**Methods:** Dynamic endorectal magnetic resonance elastography was conducted on 12 volunteers (mean age: 54, range: 34-72). The study was approved by the Institutional Research Ethics board, and all subjects provided informed consent. MR imaging in this study was first conducted on 7 volunteers in a 1.5T closed bore MR imager (Signa; GE Healthcare, Milwaukee, WI, USA) using a rigid endorectal coil (Hologic Inc., ON, Canada) and another 5 volunteers on a 3T closed bore MR imager (Discovery; Healthcare, Milwaukee, WI, USA) using an inflatable balloon type endorectal coil (Medrad Inc., PA, USA). The endorectal coil was mechanically coupled to a custom made piezoceramic actuator that was designed and manufactured in house<sup>4</sup>. Axial and sagittal T2-weighted images and diffusion weighted images (b =200-800) were acquired prior to MR elastography. Each volunteer's tolerability to vibration of the endorectal coil for short and long durations was assessed for frequencies ranging from 100-300Hz and displacements of  $\pm 1, 10, 20, 30, 40$  microns. MRE was then performed in a single slice using a modified fast gradient echo sequence with sinusoidal motion encoding gradients at the highest tolerable displacement amplitude and at 3-4 different frequencies within the given range. The imaging parameters used were a matrix size of 128x128, TR/TE = 18/13ms, a field of view of 14 cm, flip angle = 30 degrees, 1-4 motion encoding gradients (4 G/cm), number of excitations = 1-4, 4 phase offsets, a 6 mm slice thickness, and motion encoding in only 1 (4 volunteers) or 3 (7 volunteers) directions. In addition a multi-slice MRE acquisition was obtained over the entire prostate gland, using a range of frequency and imaging parameters to establish the feasibility of imaging the entire organ.

**Results:** 11 of the 12 volunteers stated that they were able to tolerate displacement amplitudes of  $\pm 40$  microns over the entire frequency range for 4-8 minutes. One volunteer ended the study early due to the need to urinate and amplitudes of up to  $\pm 30$  microns could be tested. No volunteers complained of any pain or discomfort beyond those typical experiences with the use an endorectal coil alone. Shear wave propagation was observed in the prostate gland using both endorectal designs. The rigid endorectal coil needed to be angled in a fashion such that it was firmly pressed against the rectal wall, adjacent to the prostate, in order to allow shear wave frequencies >100 Hz to propagate into the prostate. At oscillation frequencies of 100Hz shear waves would propagate into the prostate irrespective of coil positioning. The capability of the balloon type coil to be inflated while inside the volunteer allowed for better mechanical coupling of the device to the rectal wall and prostate gland. Shear wave propagation across the entire prostate was observed between 100 and 300Hz using this coil. Typical wave images and elastograms are shown in Fig. 1 for volunteers 7 (rigid coil) and 9 (inflatable coil) for frequencies of 100Hz, 200Hz, and 300Hz. Fig. 1 illustrates that as the frequency increases so does the apparent stiffness values, demonstrating the common wave dispersion phenomenon typical of viscoelastic tissues.

**Discussion and Conclusions:** Endorectal MRE is tolerable for amplitudes of  $\pm 40 \mu m$  over the 100Hz-300Hz frequency range, and shear waves can be transmitted into the prostate gland and detected with MRI using an endorectal receive coil. The maximum vibration amplitude was limited to  $\pm 40 \mu m$  in this study due to limitations with the actuator, but under these operation conditions shear waves of up to 300Hz could be generated in the prostate using either coil design. The results of this study motivate further investigation of eMRE in prostate cancer patients.

**References:** [1] Kemper et al., Rofo 2004; 176:1094-1099. [2] S. Li et al., Acta Rad. 2011; 52: 354-358. [3] Chopra et al., MRM 2009; 62:665-671. [4] Arani et al. MRM 2011; 65: 340-349

Arvin Arani was supported by the National Sciences and Engineering Research Council of Canada (NSERC) and this study was supported by the Canadian Institute of Health and Research (Grant #: PPP110821)

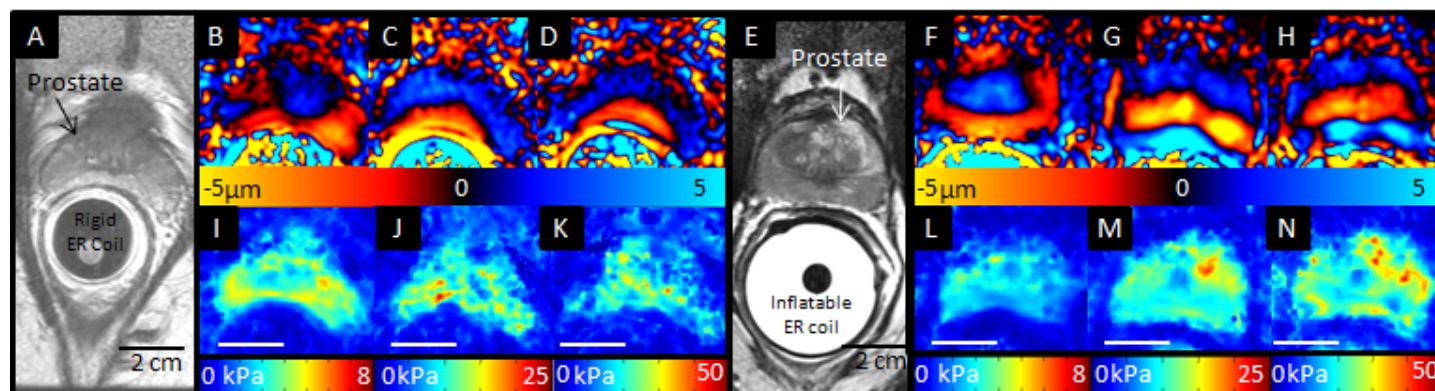


Fig. 1: A) and E) Axial pelvic T2-weighted image of volunteers 7 and 9 with inserted rigid and inflatable endorectal coils, respectively. B-D) and F-H) Wave images obtained from SI motion encoding for volunteers 7 and 9 at 100Hz, 200Hz, and 300Hz, respectively. I-K) and L-N) Respective elastograms for each volunteer with motion encoding in all three directions.