

Optimal weighting factors of the weighted subtraction in the Three-dimensional Ultrashort echo time imaging of the short T2 contrast tissue in the knee

Young Han Lee¹, Ho-Taek Song¹, Jin-suck Suh¹, and Vladimir Jellus²

¹Radiology, Severance hospital, Yonsei Univ. College of Medicine, Seoul, Seoul, Korea, Republic of, ²Siemens AG, Healthcare Sector, Erlangen, Germany

Objective

There has been an increasing interest in the images of tissues which have very short T2 relaxation times which show little or no signal with conventional magnetic resonance (MR) sequences. In current clinical machine, the acquisition of UTE sequence may be limited because of low matrix and suboptimal image quality of 3D imaging. Therefore the short T2 imaging in the clinical MR scanner requires some post-processing of the images for the suppression of the signal from surrounding long T2 species. Dual echo acquisition of the UTE with subtraction approach is simple and effective. In previous article, the rescaled subtraction of UTE has been reported with qualitative comparison of the several techniques in imaging cortical bone and the Achilles tendon of cadaveric specimens. We thought that different short T2 species may require different approaches to achieve optimal image contrast and each different tissue could be its own optimal factor. By using the optimal subtraction, weighted subtraction of UTE with an optimal weighting factor could provide high positive contrast with adequate suppression for the imaging of short T2 species.

In this paper, we investigated the feasibility to use the dual echo three-dimensional (3D) UTE sequence with weighted subtraction on a 3-T clinical MR scanner. The approaches were demonstrated in weighted subtraction images of the tendon, cartilage, cortical bone, meniscus, and infrapatellar fat pad using a 3-T clinical MR scanner. The analyses of the signal-to-noise ratios (SNRs) and contrast-to-noise ratios (CNRs) were performed to compare the images.

Method

Consecutive 47 patients underwent the knee MR dual echo 3D UTE sequence (TE of 70 μ s and 3.82 ms). Exclusion criteria included osteoarthritis, inflammatory arthritis such as rheumatoid arthritis, chondromalacia, history of knee trauma, and any kinds of knee surgery. Thirteen patients are included for determining the optimal weighting factors. For the variably weighted subtraction images of UTE, the initial UTE image is scaled down relative to that of the second long echo image with weighing factors from 0.1 to 4.0. These weighted images were reformatted on a separate workstation by dedicated software. For quantitative assessment of the weighted images of the UTE, SNR and CNR measurements were performed by the mean signal intensity inside a user-drawn region of interest (ROI) on the normal tissue of the patellar tendon, cartilage, cortical bone, meniscus, and infrapatellar fat pad.

Result

By using the subtraction image, the short T2 tissue can be visualized with adequate suppression in clinical 3T MR scanner. Considering the CNRs and SNRs, the optimal ranges of the weighting factors could be suggested: 0.8 for the delineation of the tendon, 0.4 for the delineation of the cortical bone, and 1.2 for the delineation of the meniscus, respectively. For the cartilage, the SNR of the subtraction images are much less than that of the second long echo image. The optimal weighting factor for the cartilage could not be determined with subtraction method.

Conclusion

The 3D UTE provides imaging of short T2 tissues which cannot be visualized on the conventional MR. By using the weighted subtractions with optimal weighting values, the each tissue can be optimally depicted by the overcoming the reduced T2 contrast to the fat or muscle.

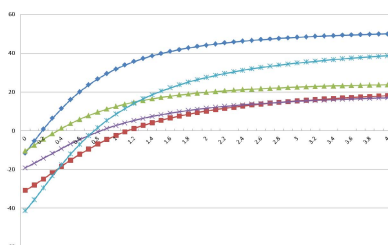


Fig. 1— Weighting factor-SNR curves

The spectral HU curves show the HU values of each prosthesis and each CT image with/without MARS. The SNRs were increased in proportion to the weighting factors.

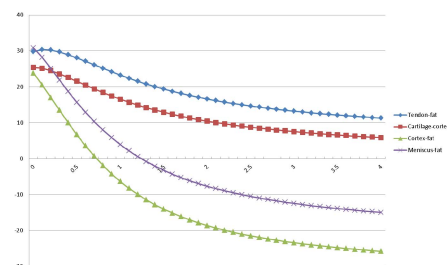


Fig. 2— Weighting factor-CNR curves

The spectral HU curves show the HU values of each prosthesis and each CT image with/without MARS. The CNRs were decreased in inverse proportion to the weighting factors.

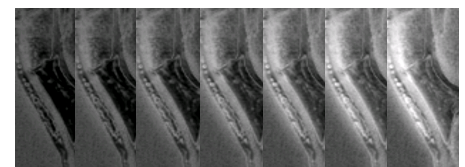


Fig. 3— Weighted subtraction image of 3D UTE of the patellar tendon. The images of consecutive weighted factors of 0.2 to 0.8 (D) shows the further increment of SNR and some decrement of CNR