

Network of spatial attention: diffusion tensor imaging study of left hemispatial neglect

Takaaki Hattori¹, Ryo Sato², Shigeki Aoki^{3,4}, and Sumio Ishiai⁵

¹Department of Neurology, Kanto Central Hospital, Setagaya-ku, Tokyo, Japan, ²Department of Radiological Sciences, Graduate School of Human Health Sciences, Tokyo Metropolitan University, Arakawa-ku, Tokyo, Japan, ³Department of Radiology, School of Medicine, Juntendo University, Tokyo, Japan, ⁴Department of Radiology, Juntendo University, Tokyo, Japan, ⁵Department of Rehabilitation Medicine, Sapporo Medical University, Sapporo, Japan

Introduction:

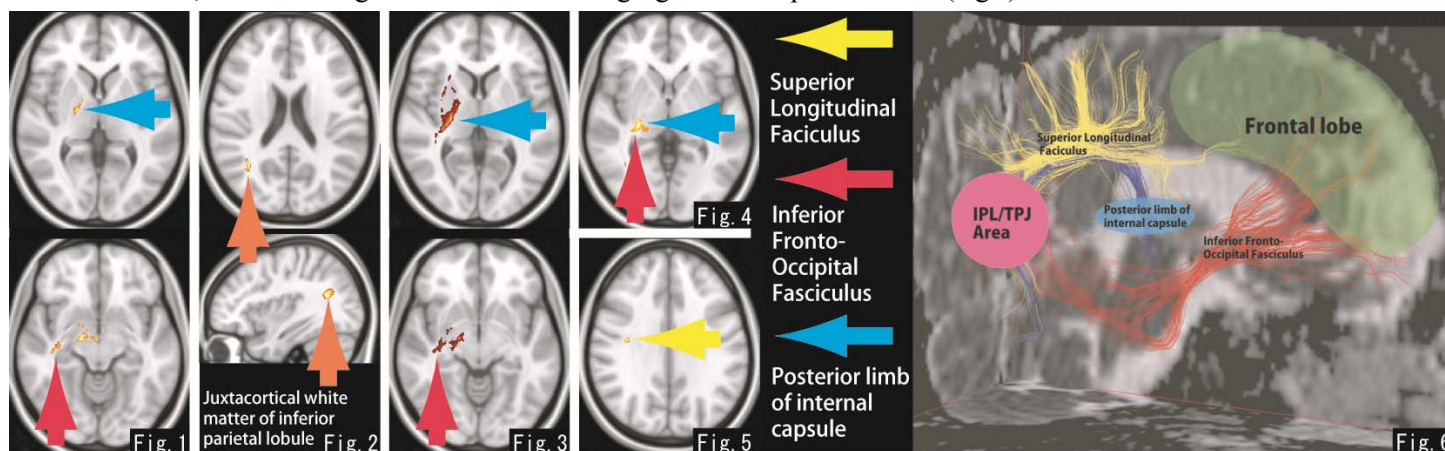
Left hemispatial neglect (neglect) is frequently seen in patients with the right hemisphere stroke. Neglect is considered to be a state of impaired spatial attention to the left space. The typical cortical regions of neglect are the inferior parietal lobule (IPL) and/or the temporal-parietal junction (TPJ) in the right hemisphere. However, other lesions, such as the frontal lobe, thalamus and white matter, can also cause neglect [1]. We aimed to elucidate the network of spatial attention by using diffusion tensor imaging.

Methods:

We enrolled right handed patients who had the first stroke in right hemisphere, Mini-Mental State Examination > 15 points and no past medical history of central nervous system. Neglect was evaluated by using paper tests (line cancellation test, line bisection test, clock drawing test and square drawing test) and activity of daily living in both acute phase (within 3 weeks) and sub-acute phase (3 weeks after stroke onset). We classified patients into either neglect group (patients with neglect for more than 3 weeks) or control group (patients without neglect). Diffusion tensor imaging (DTI, 30axis of Echo Planner Imaging, 3mm thickness) and 3 dimensional-T1 weighted imaging (3D-T1WI, sagittal image, 1mm thickness) were obtained by using 1.5T MRI (SIEMENS, Trio) at 3 weeks from stroke onset. Stroke areas were drawn on 3D-T1WI by using MRIcro, and they were superimposed in each group. Fractional Anisotropy (FA) image was generated by using FMRIB Software Library 4.1.5. FA maps were compared between neglect group and control group by using Statistical Parametrical Mapping (SPM) 8 with cost-function masking [2]. Neglect group was subcategorized into subgroups, according to whether the case includes IPL/TPJ lesions or identified lesions by SPM analysis. Remaining cases in neglect group was compared with control data by SPM analysis, and cases including the identified lesions were further classified into subgroup. We repeated this processes.

Results and Discussion:

We enrolled 35 cases in neglect group (Age: 74.0 ± 9.4 y/o, average stroke volume: 50775 mm^3) and 25 cases in control group (Age: 72.0 ± 8.4 y/o, average stroke volume: 7097 mm^3). SPM analysis of neglect group and control group showed significantly decreased FA values in the posterior limb of internal capsule (PL-IC) and the inferior fronto-occipital fasciculus (IFOF) (Fig.1). SPM analysis of neglect subgroups, with lesions in IPL/TPJ areas, with infarction in the anterior choroidal artery's territory, with infarction in the posterior cerebral artery's territory and with other lesions, showed significantly decreased FA values in the juxtacortical white matter of the IPL (Fig.2), PL-IC and IFOF (Fig.3), PL-IC and IFOF (Fig.4) and superior longitudinal fasciculus (SLF) (Fig.5), respectively. SLF and IFOF connect the frontal lobe with other lobes, including the parietal lobe. On the other hand, PL-IC includes the posterior thalamic radiation, interconnecting the thalamus and basal ganglia with the parietal cortex (Fig.6).



Conclusion:

Our results suggest that IPL/TPJ area which is connected to the frontal lobe by SLF and/or IFOF, and which is connected to the thalamus and the basal ganglia by PL-IC is the network of spatial attention. Damage and/or disconnection of this network may cause neglect.

References: [1] Doricchi F et al., Cortex, 2008, 44(8):983, [2] Andersen SM et al., Neuroimage, 2010, 53(1):78