

Analysis of ADC Change During Cardiac Cycle in Idiopathic Normal Pressure Hydrocephalus: Change In Tap Test

Akihiro Asano¹, Toshiaki Miyati¹, Naoki Ohno², Kan Hirohito³, Mitsuhiro Mase⁴, Tomoshi Osawa⁵, Harumasa Kasai³, Nobuyuki Arai³, Masaki Hara³, and Yuuta Shibamoto³

¹Department of Health Science, Graduate School of Medical Science, Kanazawa University, Kanazawa, Japan, ²Department of Radiological Technology, Kanazawa University Hospital, Kanazawa, Japan, ³Department of Radiology, Nagoya City University Hospital, Nagoya, Japan, ⁴Department of Neurosurgery and Restorative Neuroscience, Graduate School of Medical Sciences, Nagoya City University, Nagoya, ⁵Department of Neurosurgery and Restorative Neuroscience, Graduate School of Medical Sciences, Nagoya City University, Nagoya, Japan

INTRODUCTION:

We have reported that the apparent diffusion coefficient (ADC) obtained from diffusion MRI in the cerebral white matter significantly changed during the cardiac cycle, and this change (delta-ADC) assisted in the diagnosis of idiopathic normal pressure hydrocephalus (INPH) [1]. While a cerebrospinal fluid tap test is one of the useful methods for the diagnosis of INPH. The aim of this study was to assess how much change in the delta-ADC of the brain in INPH before and after the tap test.

METHOD AND MATERIALS:

On a 1.5-T MRI, electrocardiogram-triggered single-shot diffusion echo planar imaging ($b = 0$ and 1000 s/mm^2) was used with parallel imaging and half-scan techniques to minimize the sampling window. Then delta-ADC image was calculated from the maximum-minus-minimum ADC value of all cardiac phase images (20 phases) on a pixel-by-pixel basis. The delta-ADC and ADC in the frontal white matter were determined in patients with INPH ($n = 12$) before and after tap test except periventricular high intensity area on the T2 weighted image.

RESULTS AND DISCUSSION:

Delta-ADC in the INPH after the tap test was significantly lower than those before the tap test. This result shows that the water molecules in the white matter in INPH before tap test were easily fluctuated by the blood volume loading compared to INPH after tap test due to the increase in the intracranial compliance. Furthermore this result also suggests delta-ADC may noninvasively predict the clinical response to the shunt surgery. However, there was no significant difference in ADC values in INPH before and after the tap test.

CONCLUSION:

Delta-ADC analysis makes it possible to noninvasively provide information of change in the intracranial condition after the tap test, and may assist to predict the clinical response to the shunt surgery.

REFERENCES:

[1] Ohno N, et al., *Radiology*, 2011; 261(1): 560-565. [2] Miyati T, et al., *J Magn Reson Imaging* 2007; 26: 274-278.

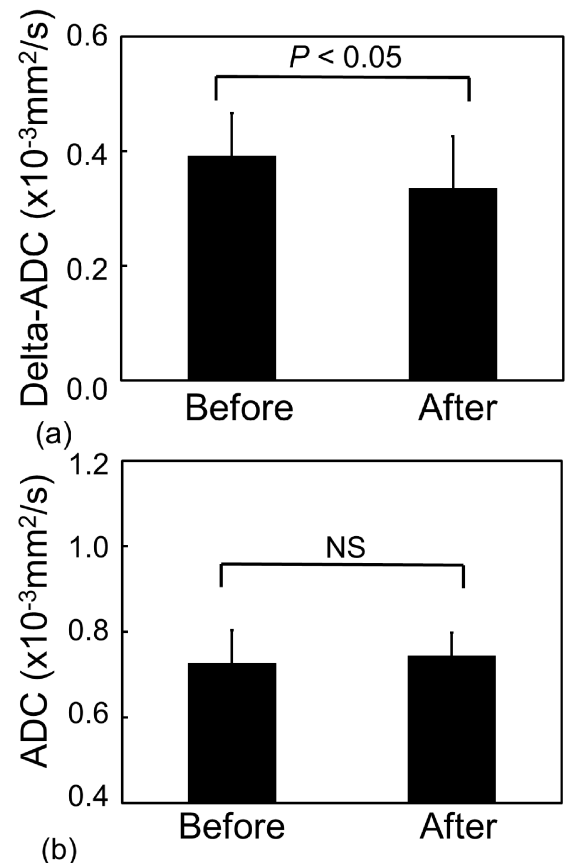


Fig. 1 (a) Delta-ADC and (b) ADC value before and after tap test.

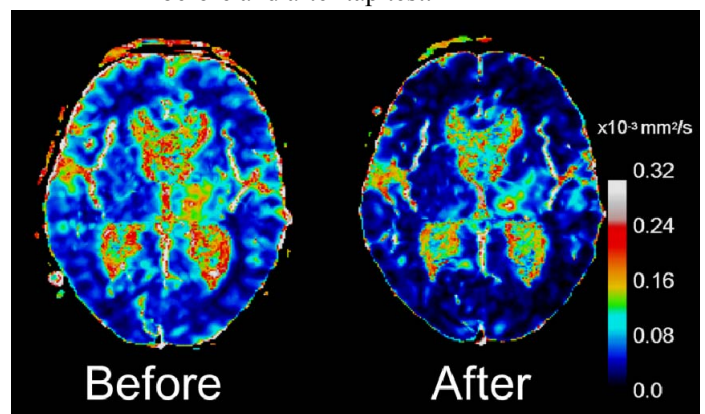


Fig. 2 Typical examples of delta-ADC images before and after tap test.