

Time-dependent cell invasion, motility, and proliferation level estimate (CIMPLE) map characteristics of malignant gliomas treated with paclitaxel poliglumex (PPX)

Benjamin M Ellingson¹, Jerrold L Boxerman², Suriya Jayapalan³, Heinrich D Elinzano³, Marc Goldman⁴, Thomas Dipetrillo⁵, Howard Safran⁶, and Whitney B Pope¹
¹Radiological Sciences, David Geffen School of Medicine, University of California, Los Angeles, Los Angeles, CA, United States, ²Diagnostic Imaging, Brown University and Rhode Island Hospital, ³Neurooncology, Brown University and Rhode Island Hospital, ⁴Neurosurgery, Brown University and Rhode Island Hospital, ⁵Radiation Oncology, Brown University and Rhode Island Hospital, ⁶Hematology & Oncology, Brown University and Rhode Island Hospital

Introduction

Paclitaxel poliglumex (PPX; Cell Therapeutics, Inc., Seattle, WA) is a microtubule stabilizer and mitotic inhibitor with a radiosensitization index of 4-8, and has been proposed as a radiosensitizing agent for patients with high-grade gliomas undergoing radiation therapy with the purpose of increasing acute cytotoxicity and effectiveness of radiotherapy. Initial observations of PPX-treated gliomas demonstrated substantial transient increases in the degree and number of contrast enhancing lesions, many of which were later found to be quiescent tumor or due to treatment-related changes in the tumor mimicking progressive disease (i.e. pseudoprogression). The purpose of the current study was to determine whether time-dependent cell invasion, motility, and proliferation level estimate (CIMPLE) maps derived from serial diffusion MRI data ^{1,2} could distinguish pseudoprogression from recurrent tumor in a phase II study of PPX added to standard IMRT and TMZ therapy for newly diagnosed high-grade (WHO III-IV) gliomas.

Methods

All patients participating in this study signed institutional review board-approved informed consent. A total of 15 histologically-confirmed high-grade glioma patients with diffusion MR images before and after completion of PPX and who demonstrated progressive post-PPX enhancement by RANO criteria were included in the current study. All images for each patient were registered to a high-resolution (1.0 mm isotropic), T1-weighted brain atlas (MNI152; Montreal Neurological Institute) using a mutual information algorithm and a 12-degree of freedom transformation using FSL (FMRIB, Oxford, UK; <http://www.fmrib.ox.ac.uk/fsl/>). Fine registration was then performed using a Fourier transform-based, 6-degree of freedom, rigid body registration algorithm followed by visual inspection to ensure adequate alignment. Time-dependent CIMPLE map estimates of proliferation rate, $\rho(n)$, were generated from three sequential ADC maps evaluated over time using a moving three scan window according to previously developed algorithms outlined below:

$$\rho(n) = -\frac{1}{ADC^{n-1}} \left(\frac{d}{dt} ADC^{n-1} - D(n) \nabla^2 ADC^{n-1} - \nabla D(n) \nabla ADC^{n-1} \right) \quad \text{where} \quad D(n) = \frac{\frac{d}{dt} ADC^n - \lambda \frac{d}{dt} ADC^{n-1}}{\nabla^2 ADC^n - \lambda \nabla^2 ADC^{n-1}} \quad \text{is a}$$

$$\frac{d}{dt} ADC^{n-1} = \frac{ADC^{n-1} - ADC^{n-2}}{t^{n-1} - t^{n-2}} \quad \text{describes the time-rate of}$$

time-dependent estimate of cell motility (diffusion), $\lambda = \frac{ADC^n}{ADC^{n-1}}$ describes the ratio of ADC on the current day, n , with respect to the previous scan day $n-1$. Thus, using three ADC maps collected on days n , $n-1$, and $n-2$, proliferation rate as a function of time $\rho(n)$ can be directly estimated on a voxel-wise basis. The largest extent of each spatially distinct contrast-enhancing lesion was contoured for CIMPLE map evaluation, and each enhancing lesion was evaluated separately to determine tumor recurrence.

Results

Voxel-wise estimates of proliferation rate as a function of time using CIMPLE maps allows for quantification of heterogeneous treatment responses within the same lesion. As demonstrated in *Fig. 1A*, voxels suspected of tumor growth demonstrate an increase in proliferation rate as a function of time, suggesting an accelerated tumor growth in these regions. Alternatively, as demonstrated within the same lesion in *Fig. 1B*, voxels thought to have an increase in contrast enhancement due to treatment-related changes demonstrates a decrease in proliferation rate as a function of time. In enhancing lesions either histologically confirmed to be recurrent tumor or suspected to be such based on clinical or temporal imaging features, the average time-dependent proliferation rates appeared to be increasing and positive within the majority of the enhancing lesion, as illustrated in the patient represented on the top of *Fig. 2*. Alternatively, in lesions either histologically confirmed to be pseudoprogression or with a waxing and waning appearance, the mean proliferation rate was low or steadily decreasing over time, as illustrated on the bottom of *Fig. 2*. In a few cases, an increase in mean proliferation rate was observed prior to increases in contrast enhancement, suggesting CIMPLE map estimates of proliferation rate may be sensitive to early changes in tumor growth otherwise not observed with standard imaging.

Discussion

Time-dependent CIMPLE map estimates of proliferation rate is a unique and potentially promising biomarker for studying PPX treatment response in individual high-grade glioma patients. In particular, results from the current study suggest time-dependent CIMPLE maps may be useful for differentiation between pseudoprogression and true tumor progression in high-grade gliomas, since we observed a relatively high frequency of pseudoprogression in patients treated with PPX compared with standard treatment.

References

1. Ellingson, *et al.*, Magn Reson Med 2011. 2. Ellingson, *et al.*, J Neurooncol 2011.

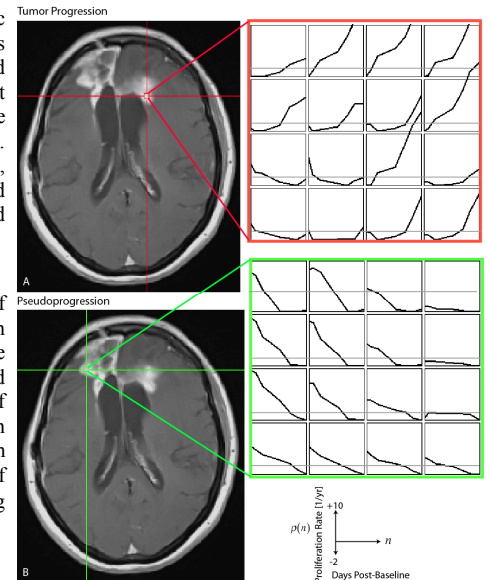


Figure 1: Voxel-wise, time-dependent CIMPLE map estimates of proliferation rate in two different regions within the same tumor treated with PPX. In this patient, two different regions within the same lesion demonstrate drastically different tumor dynamics as measured with CIMPLE maps. A) The region on the left side of the corpus callosum illustrates increasing proliferation rate, suggesting tumor progression in this region. B) In the right hemisphere, near the site of the original tumor resection, proliferation rate estimates were decreasing over time, suggesting treatment-related changes.

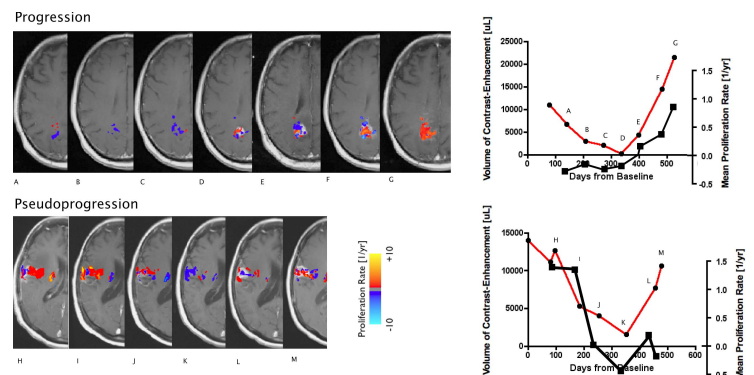


Figure 2: Time-dependent CIMPLE map estimates of proliferation rate in malignant glioma patients treated with PPX. In PPX patients with tumor progression over the evaluation period, CIMPLE map estimates of proliferation rate tended to increase over time (black line), coinciding with the increase in contrast enhancement (red). In patients with histologically or radiographically determined pseudoprogression (bottom), CIMPLE map estimates of proliferation rate tended to decrease over time (black line), even when the volume of contrast enhancement increased (red line).