

Time-Resolved 3D Fetal Imaging: Preliminary Results

Jing Liu¹, Orit Glenn¹, and Duan Xu¹

¹University of California San Francisco, San Francisco, CA, United States

INTRODUCTION

Fetal MR imaging is very challenging due to the movement of the fetus and the breathing motion from the mother. Current clinical protocols involve quick scouting scans for placement and re-orientation scans trying to capture images before the fetus moves. This is inadequate and results in long scan times in order to obtain images that are of diagnostic quality. This aim of this study is to develop a fast 3D fetal imaging technique to resolve the challenge of the moving fetus. A multi-echo radial sampling in the k_x - k_y plane with Cartesian slice encoding has been developed for 3D cardiac cine imaging [1-2]. Multi-echo radial sampling has high data acquisition efficiency and the utilization of a golden-ratio based projection profile allows flexible time-resolved image reconstruction with arbitrary temporal resolution at arbitrary time points as well as with high SNR and CNR [3]. Radial acquisition has advantages of motion robustness and flexibility for time-resolved image reconstruction with k-space center acquired at every TR. In this study, we apply this technique to in vivo fetal MRI and aim to further develop motion compensation methods to improve the image quality.

MATERIALS AND METHODS

With the multi-echo radial sequence, image data was acquired during a continuous scan of 3 minutes with the mother breathing freely. Time-resolved 3D images were reconstructed using a sliding window whose footprint can be flexibly chosen. The time frame

with minimal motion artifacts were selected retrospectively for the final visualization as demonstrated with our preliminary results. Scan parameters were: TR = 3.7ms, FA = 40°, BW = \pm 125kHz, FOV = 26 cm, spatial resolution = 1.0 \times 1.0 \times 3.0 mm, 24 slices, on a 1.5T GE EXCITE 14M3 scanner with an 8-channel cardiac coil. Data were acquired during a 3-minute scan and reconstructed into time-resolved 3D images of a 9 s temporal resolution by applying an iterative temporal filtering [4].

RESULTS AND DISCUSSION

Fig. 1 shows preliminary results of time-resolved 3D fetal images in a 23 gestational week fetus. Seven representative time frames of the axial views of the fetal brain are displayed. It can be observed that the fetus was moving during the scan. The movement is more obviously observed at the 3-plan reformatted views in Fig. 2, showing three time frames (9 s, 90 s and 171 s). The fetus at the frame of 171 s had more blurring motion artifacts.

Residual motion artifacts still exist at each time frame with an image reconstruction window of 9 s, which is long enough to encounter both maternal and fetal motion. Maternal motion may include voluntary or respiratory motion that can be considered to be translational corresponding to the fetus. Cartesian mapping of the k-space centers along the slice encoding direction provides intensity-weighted position information, from which the translational motion presented within FOV can be tracked and used for gating [1]. In Fig. 3, an example of the intensity profile along slice encoding direction is shown and the corresponding motion signal is extracted by applying principle component analysis on the intensity profile. Two superimposed motions occurring at different frequencies are shown in Fig. 3, and likely represent maternal respiratory and cardiac motions.

The fetus' motion is momentary and can be both translational and rotational. With the time-resolved 3D images, the fetus's movement cross the time frames can be registered by deriving the rigid transforms (both translation and rotation) between time frames. Image quality can be improved by combining rigidly transformed 3D volumes.

CONCLUSIONS

Our preliminary results demonstrate that the images of the fetus obtained in vivo can be retrospectively selected with the time-resolved images. Gating signals can be derived from the image data and applied for motion compensation. Image registration of the time-resolved 3D images can be explored to further improve the image quality and data acquisition efficiency. Higher temporal resolution and higher spatial resolution (such as 1 mm isotropic) need to be further evaluated.

REFERENCES

1. J Liu, et. al., MRM, 63, p1230.
2. J Liu, et. al., JMRI, 32, p434.
3. S Winkelman, et. al., IEEE-TMI, 26, p68.
4. J Liu, et. al., IEEE-TMI, 25, p148.

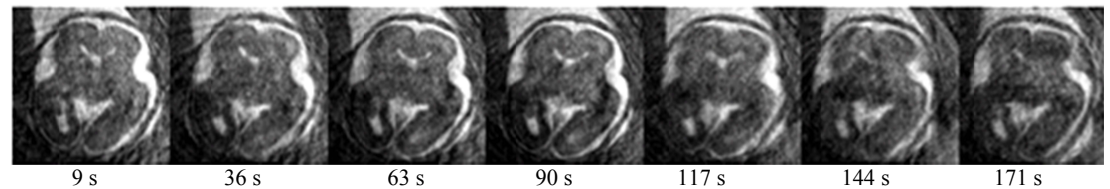


Fig. 1 Time-resolved 3D fetal images were acquired during a 3-minute scan. 20 frames were reconstructed, with a temporal resolution of 9 s. Seven representative frames at every 4 frames are shown. It can be observed that the brain has turned slightly towards the midline over the course of the scan.

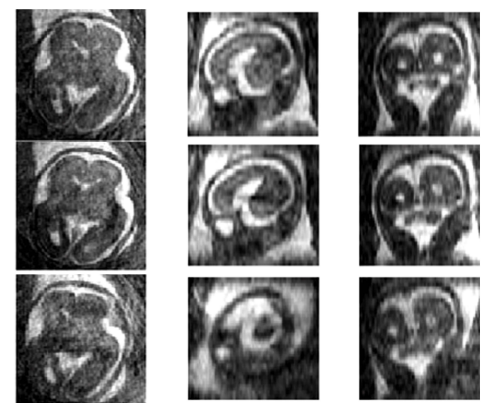


Fig. 2 Reformatted views in 3 planes of the fetus at three representative time frames: 9 s (top row), 90 s (middle), and 171 s (bottom).

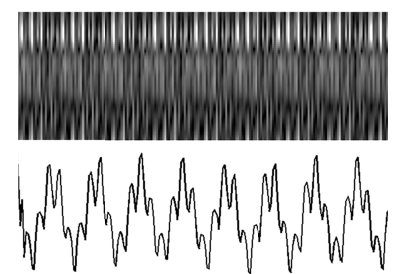


Fig. 3 The intensity profile along slice encoding direction (top) and the extracted motion signal (bottom).