

# Characterizing White Matter Abnormalities in Boys with Autism Spectrum Disorders Using Diffusion Tensor Imaging

Sung-Yeon Park<sup>1</sup>, Se-Hong Oh<sup>1,2</sup>, Young-Shin Kim<sup>3</sup>, Young-Bo Kim<sup>1</sup>, Keun-Ah Cheon<sup>4</sup>, and Zang-Hee Cho<sup>1</sup>

<sup>1</sup>Neuroscience Research Institute, Gachon University of Medicine and Science, Incheon, Korea, Republic of, <sup>2</sup>Department of Radiology, University of Pennsylvania, Philadelphia, Pennsylvania, United States, <sup>3</sup>Child Study Center, Yale University School of Medicine, New Haven, Connecticut, United States, <sup>4</sup>Department of Child and Adolescent Psychiatry and Institute of Behavioral Science in Medicine, Yonsei University College of Medicine, Seoul, Korea, Republic of

**Introduction:** Autism spectrum disorders (ASD) are characterized by qualitative impairments of reciprocal social interaction and deficits in communication, and stereotyped or repetitive patterns of behavior. The pathophysiology of ASD remains unclear, but the hypothesis that ASD represents a disorder of neuronal connectivity [1-2] is supported by converging data using the Diffusion Tensor Imaging (DTI), a non-invasive MRI technique for in vivo mapping of white matter structures. However, there is still lack of evidence showing strong relation to abnormalities in white matter structural integrity with autism even though replicating study to support those abnormalities currently are increasing by using the DTI technique. In this study, we aimed to examine the difference of white matter integrity between left and right hemispheres using the DTI in a sample of Korean boys with high functioning ASD and age and sex matched healthy controls. We hypothesized that the white matter integrity difference between left and right hemispheres would be abnormal in ASD subjects compared to the healthy control subjects. We also examined several white matter structures that underlie social processing and the principal cerebral commissure, the CC, to confirm previous reports of abnormality in these tracts.

**Materials and Methods:** We enrolled thirty four male subjects (17 ASD patients and 17 typically developing controls; see Table 1). We performed MRI scans using a 1.5T clinical MRI scanner (Avanto 1.5T, Siemens, Erlangen, Germany). 12-channel head matrix coil was used for study. Diffusion weighted images were acquired using a spin-echo based single-shot echo-planar diffusion sequence. The DTI pulse sequence used dual bipolar diffusion gradient pulses and a double spin echo to suppress eddy current induced artifacts. The specific MR imaging parameters used were: TR = 6500 ms; TE = 86 ms; number of diffusion gradient directions = 30; b value = 900 s/mm<sup>2</sup>; number of excitations = 2; GRAPPA factor = 2. The in-plane resolution was 1.8x1.8 mm, and the slice thickness was 3 mm without gap. Acquired diffusion data were preprocessed using FMRIB Software Library (FSL, Oxford, United Kingdom). Voxel-based group differences were performed separately on the FA, MD images of all subjects using Tract-Based Spatial Statistics (TBSS). For statistical inference, including correction for multiple comparisons across space, we used permutation testing on our data implemented in RANDOMISE, a part of the FSL software package. Correction for multiple comparisons and cluster formation preceded with threshold-free cluster enhancement (TFCE), which avoids using an arbitrary threshold for the initial cluster-formation. Regions of interest (ROIs) were defined in the CC, inferior longitudinal fasciculus (ILF), and uncinate fasciculus (UF). Regions were created by overlying the TBSS-generated skeleton from the Johns Hopkins University DTI-based probabilistic tractography atlas for the tracts of interest [3].

**Results:** As shown in Table 1, the groups did not differ significantly on age, IQ, handedness, or head circumference. In whole-brain voxel-wise analyses, FA was significantly reduced and MD was significantly increased in the CC, left ILF, and left UF in subjects with ASD compared to typically developing boys. To confirm these VBM analysis results we did individual ROI data based independent t-test in CC, UF and ILF regions. As shown in Table 2 and Fig. 1, ROI-based analyses revealed significantly lower FA in CC, left UF, and right and left ILF, and significantly higher MD values of the CC in the ASD group compared to the healthy control group. We could find one more information in Fig.1, the differences between two groups are much significant at the left side. And compared with FA value of the left and right hemisphere in each group, control group shows big difference (see white columns of the Fig.1 (a) and (b)) but ASD group shows not much difference (see pink columns of the Fig.1 (a) and (b)). Based on these findings, we calculated lateralities between left and right hemispheres in each group. The laterality function can be written as:

$$\text{Laterality} = \frac{FA_L - FA_R}{FA_L + FA_R}$$

where the  $FA_L$  and  $FA_R$  represents the mean FA value of each ROI, which defined at the left and right hemisphere, respectively. The ROIs were manually defined based on anatomical information at each hemisphere. In Fig. 2, the difference of laterality between ASD and control group was significant in UF and ILF. As shown, the group differences of FA values in the left hemisphere were significant but the differences in the right hemisphere were not significant.

**Conclusions:** In the present study, we found that FA in the CC, left UF and left and right ILF were significantly lower in subjects with ASD than healthy control subjects in both whole-brain voxel-wise analyses and ROI-based analyses. These findings, which showed significant reduction of FA in white matter structure related social cognition in ASD subjects compared control subjects support previous findings that social brain structure may be disrupted in ASD. In addition, the differences of FA values between left and right hemispheres in the same ROI regions were reduced in ASD group. And it mainly affected by a reduced FA value of left hemisphere. Reductions in DTI fractional anisotropy (FA) are believed to reflect less myelinated and less mature white matter tracts. Therefore, our new finding suggests that, the ASD patients may have abnormal white matter integrity in the left hemisphere. These findings will help on understanding of more advanced neurobiological basis underlying the social deficits in ASD. Nevertheless, we will still need to focus on evaluating the association between each symptom shown in ASD individuals and brain abnormalities in the future study.

**References:** [1] Brun, C.C. et al., Hum Brain Mapp. 2009 ;30, 3887-900. [2] Gepner, B. et al. Neurosci Biobehav Rev. 2009 ;33, 1227-42. [3] Mori, S., MRI Atlas of Human White Matter. 2005; Elsevier **Acknowledgements** This research was supported by Basic Science Research Program Through the National Research Foundation (NRF) funded by the Ministry of Education, Science and Technology (20110030089).

		ASD (n=17) Mean±SD	Control (n=17) Mean±SD	p-value
AGE (range)		11.0 ± 2.1 (8-14 yrs)	10.2 ± 2.0 (8-14 yrs)	.25
IQ (range)	Verbal IQ	114.5 ± 9.7 (95-132)	111.2 ± 10.6 (94-130)	.36
	Performance IQ	106.6 ± 15.2 (81-131)	109.6 ± 13.0 (87-135)	.53
	Total IQ	112.1 ± 12.0 (89-129)	113.8 ± 11.0 (91-136)	.67
Head Circumference (cm)		55.3 ± 1.1	55.2 ± 1.5	.82
Handedness	Left/Right	1/17 (5.9%)	1/17 (5.9%)	1.0

Table1. Demographic data of the subjects.

	FA			MD (×10 <sup>-3</sup> mm <sup>2</sup> /s)		
	ASD (n=17) Mean±SD	Control (n=17) Mean±SD	p	ASD (n=17) Mean±SD	Control (n=17) Mean±SD	p
CC	0.589±0.064	0.664±0.041	.000**	2.631±0.274	2.39±0.142	.002**
UF (left)	0.495±0.084	0.582±0.034	.000**	2.124±0.178	2.021±0.110	.051
UF (right)	0.534±0.062	0.553±0.050	.329	2.056±0.137	2.065±0.140	.853
ILF (left)	0.438±0.051	0.543±0.049	.000**	2.219±0.187	2.196±0.151	.693
ILF (right)	0.466±0.046	0.498±0.037	.037**	2.148±0.142	2.230±0.206	.187

Table2. FA and MD in individual regions of interest (UF: uncinate fasciculus, ILF: inferior longitudinal fasciculus)

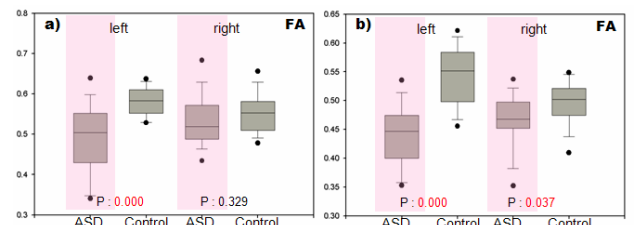


Fig.1. Individual ROI based group comparison results. (Independent t-test, (a) Uncinate fasciculus and (b) Inferior longitudinal fasciculus.)

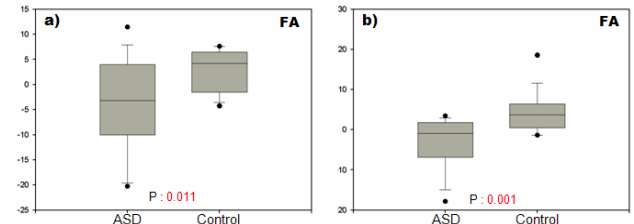


Fig.2. Comparison result of laterality between ASD and healthy control group in (a) Uncinate fasciculus and (b) Inferior longitudinal fasciculus.