

Biophysical Abnormalities in Normal-Appearing White Matter and Subcortical Nuclei in Late-Life Major Depression: A Magnetization Transfer Imaging Study

Shaolin Yang^{1,2}, Olusola Ajilore¹, Minjie Wu¹, Melissa Lamar¹, and Anand Kumar¹

¹Department of Psychiatry, University of Illinois at Chicago, Chicago, IL, United States, ²Department of Radiology, University of Illinois at Chicago, Chicago, IL, United States

Introduction

Major depression is one of the most common mental disorders in the elderly population. Studies using magnetic resonance imaging (MRI) have demonstrated decreased volume of focal brain regions, such as prefrontal lobe, hippocampus and the head of caudate nucleus, and increased volume of white matter hyperintensity lesions compared to controls [1,2]. Magnetization transfer (MT) imaging is a MRI technique that can provide estimates of myelin & axonal density in white matter and protein & cell membrane composition in gray matter [3]. MT imaging exploits the fact that there are two types of water within biological tissues, i.e., water bound to slowly moving macromolecules (bound water) and water relatively free to move in biological compartments (free water), and that individual water molecules exchange back and forth between the two pools [4]. The magnetization transfer ratio (MTR) imaging involves two acquisitions, one like a routine MRI and the other one with an “off-resonance” pre-saturation pulse on bound water. The MTR or MT contrast is usually lower in biological tissue in diseases characterized by injury in white matter or gray matter. There are a few MTR imaging studies on late-life depression [4-6], however, the population size was too small and/or the data acquisition was performed at 1.5T. The current study was to expand on our previous MTR imaging studies on late-life depression but with a larger subsection population and at higher field strength 3T. We hypothesized that MTR would be significantly lower in critical white matter regions and subcortical nuclei in patients with late-life major depression compared with control subjects.

Materials and Methods

The study groups consisted of 17 patients with late-life major depression (11 women, mean age=66.2, SD=8.7) and 26 nondepressed comparison subjects (15 women, mean age=67.5, SD=5.4). All subjects were age 60 or older and their mean Mini-Mental State Examination scores were in the normal range (mean±SD=29.1±1.2 in patients; 28.8±1.3 in controls). All depressed patients met DSM-IV criteria for major depression and had scores of 18 or greater on the 17-item Hamilton Depression Rating Scale (HAM-D). These subjects were recruited from relevant clinics and local area community and the consent form had been acquired from all subjects.

The MRI scans were performed on a Philips Achieva 3T scanner with a SENSE-Head-8 coil. The MT images are acquired using a three-dimensional (3D) spoiled gradient-echo echo-planar imaging sequence. The sequence parameters are TR/TE = 64/15 ms, flip angle = 9°, FOV = 24 cm, 67 axial slices, slice thickness = 2.2 mm/no gap, off-resonance frequency of the RF pre-saturation pulse = 1500 Hz [7,8]. Regions of interest (ROI) were put in left and right anterior cingulate, dorsolateral frontal white matter, occipital white matter, head of caudate nucleus and putamen, and bilateral genu and splenium.

Differences in the MTR values between subject groups were assessed using analysis of covariance (ANCOVA) controlling for age, sex, and education. All statistical analyses were carried out using SPSS ver. 18. Significant level was set at 0.05.

Results and Discussion

The two groups did not differ in age ($F_{1,41}=0.38$, $p=0.54$), gender ($\chi^2=0.21$, $p=0.65$), and education ($F_{1,41}=0.009$, $p=0.93$). The MTR values were significantly lower in the genu of corpus callosum (-3.6%, $F_{1,39}=4.50$, $p=0.04$) and the right head of caudate nucleus (-4.8%, $F_{1,39}=8.78$, $p=0.005$) in patients with late-life major depression than the control subjects. The MTR values were also lower (approaching significance) in the left anterior cingulate (-4.6%, $F_{1,39}=3.83$, $p=0.058$) and the left head of caudate (-2.1%, $F_{1,39}=3.34$, $p=0.075$) than the controls. No other regions exhibited significant (or approaching significant) difference in the MTR values between groups, although the mean MTR values in most of other regions were lower in patients than the controls. These findings suggest late-life major depression is associated with compromised macromolecular proteins in white matter and subcortical nuclei and may have implications for the pathophysiology of late-life major depression.

References

- [1] Ajilore O et al., Neuropsychopharmacology 2007; 32:1224-1231. [2] Haroon E et al., Psychiatry Res. 2009; 171:10-19. [3] Kumar A, et al., Arch Gen Psychiatry, 2009; 66:324-330. [4] Kumar A, et al., Psychiatry Res. 2004, 130:131-140. [5] Wyckoff N, et al., J Magn Reson Imaging, 2003, 18:537-543. [6] Gunning-Dixon FM, et al., AM J Geriatr Psychiatry, 2008, 16:255-262. [7] Reich DS, et al., Am J Neuroradiol, 2006, 27:2166-2178. [8] Smith SA, et al., Magn Reson Med, 2006, 56:866-875.

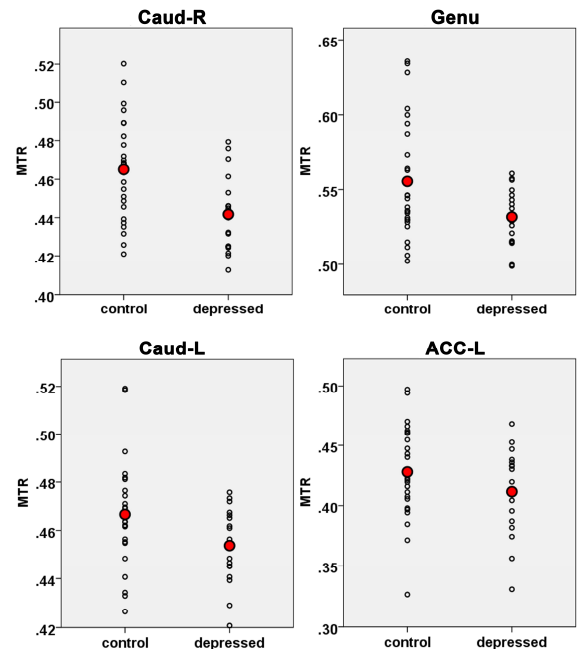


Fig. 1. Significantly lower MTR values in right head of caudate (Caud-R) and genu of corpus callosum (Genu) and approaching significantly lower MTR values in left head of caudate (Caud-L) and left anterior cingulate cortex (ACC-L)