

Comparison of Artifacts Caused by Biopsy Markers on Breast MRI with Different Fat Suppression Techniques

Yuan Le¹, Hal D Kipfer², Shadie S Majidi², Stephanie Holz², and Chen Lin¹

¹Radiology, Indiana University, Indianapolis, Indiana, United States, ²Radiology and Imaging Science, Indiana University, Indianapolis, Indiana, United States

Introduction: Biopsy markers are frequently encountered in breast MR exams. They cause local magnetic field inhomogeneity and introduce artifacts, especially in fat suppressed dynamic contrast images. The severity of the artifact depends on the magnetic susceptibility of the materials, the position of the marker, and the technique and parameters used for imaging [1-3]. The purpose of this study is to compare the appearance of biopsy marker artifact in images with three different types of fat-suppression techniques: 1) conventional or Quick FatSat (QFS), 2) SPectrally selective Adiabatic Inversion Recovery (SPAIR) [4], and high receiver bandwidth dual-echo Dixon [5] implemented in a novel pulse sequence, TWIST Dixon, using time-resolved angiography with stochastic trajectories (TWIST) [6] for k-space data sharing and acceleration..

Material and Method: Phantom Study: A breast phantom was constructed using uniform water-fat emulsion according to a published method [7-8]. Two different biopsy markers (SecurMark® stainless steel and ATEC® TriMark® titanium Hologic, Toronto, Canada) were embedded into the phantom (Fig. 1). Imaging was performed on a clinical 3T scanner (TIM Verio, Siemens, Germany) with an 8-channel breast coil (Hologic, Toronto, Canada). 3D T1 weighted spoiled gradient echo images were acquired with: (1) TWIST-Dixon; (2) VIBE with SPAIR fat suppression (VIBE-SPAIR), and (3) VIBE with conventional fat suppression (VIBE-QFS). In each set of images, the mean (μ) and standard deviation (σ) of signal intensity was first obtained in an area around the markers but free of artifacts (the cross section of 3D ROI is shown as areas between two red-line circles in Fig. 1). The voxels around the markers with signal intensity out of the range of $\mu \pm 2\sigma$ were counted as either bright or dark artifacts, respectively. Patient Study: As part of an Institutional review board approved clinical study of TWIST Dixon application in breast MRI. Five patients were found to have biopsy markers (One of them also have a chemotherapy port). Patient exams were carried out on the same scanner but with a 7 channel breast coil (Invivo, Gainesville, FL) where TWIST Dixon and VIBE-SPAIR images were acquired. Artifacts in patient images were qualitatively evaluated by three radiologists.

Results: In TWIST-Dixon images, the biopsy marker artifacts appear as a signal void with a thin bright rim, while the artifacts in VIBE-SPAIR and VIBE-QFS images are interleaved bright and dark rings (Fig. 2). TWIST-Dixon has the smallest total artifact (Table 1). Fig. 3 shows the artifacts from a marker and a chemotherapy port in patient images acquired with TWIST Dixon and VIBE with SPAIR fat suppression. The area of the artifact due to the presence of a port is larger in VIBE SPAIR images than TWIST Dixon images. Evaluation of patient images also found that TWIST-Dixon produces a larger dark center in the artifacts, allowing them to be easily recognized, while the overall size of the artifact in TWIST Dixon images are not different from that in VIBE-SPAIR images.

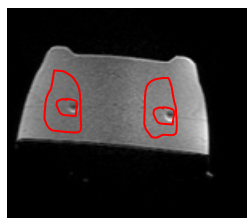


Figure 1 Marker Phantom. Red lines show the cross-section of the 3D ROIs for μ/σ calculation and artifact counting.

Table 1 Artifact size and intensity for two markers

		TWIST Dixon	VIBE-SPAIR	VIBE-QFS
Stainless Steel Marker	Dark Pix No.	556	875	632
	Bright Pix No.	192	173	231
		Total	1048	863
Titanium Marker	Dark Pix No.	347	860	406
	Bright Pix No.	147	127	114
		Total	987	520

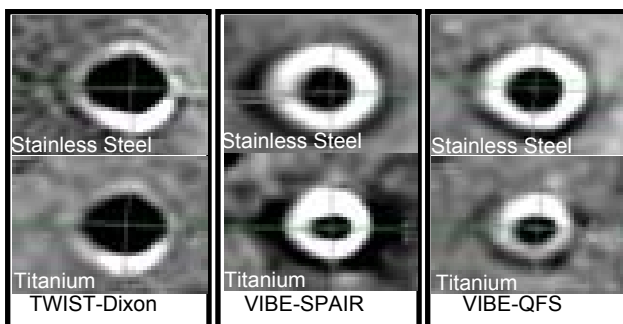


Figure 2. Artifact from biopsy markers.

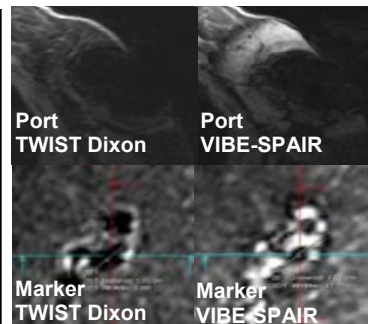


Figure 3 Port and marker artifact in patient images.

Discussion: Biopsy markers do introduce artifacts of different type and size with different fat-suppression techniques. The central dark region appears smaller with fat suppressed gradient echo images than TWIST Dixon because of the bright ring from un-suppressed fat signal. The Dixon based method produces a larger central void, allowing the markers to be easily identified, but has a smaller overall volume, obscuring less surrounding anatomy and pathology. Such feature could be an additional advantage for TWIST Dixon in breast MRI of patients with biopsy marker. However, it's hard to draw statistical significant conclusions from the limited number of patients in the study until more data becomes available.

Reference 1.Ghate, S.V., et al., *Acad Radiol*, 2011. **18**(6): p. 770-3. 2.Shellock, F.G., *AJR Am J Roentgenol*, 1999. **172**(5): p. 1417-9. 3.Genson, C.C., et al., *AJR Am J Roentgenol*, 2007. **188**(2): p. 372-6. 4.Balchandani, P. et al. *Magn Reson Med*, 2008. **59**(5): p. 980-8. 5. Dixon, W.T., *Radiology*, 1984. **153**(1): p. 189-94. 6.Herrmann, K.-H., et al., *ISMRM* 2010: p. 2503. 7.Bernard, C.P., et al., *J Magn Reson Imaging*, 2008. **27**(1): p. 192-7. 8.Yu, H., et al., *J Magn Reson Imaging*, 2010. **31**(5): p. 1264-71.