

Probing tumor early response to radiation therapy using hyperpolarized [1-¹³C]pyruvate in a breast cancer model

Albert P Chen¹, Yi-Ping Gu², Michelle Ladouceur-Wodzak², William Chu³, and Charles H Cunningham^{2,4}

¹GE Healthcare, Toronto, ON, Canada, ²Imaging Research, Sunnybrook Health Sciences Centre, Toronto, ON, Canada, ³Radiation Oncology, University of Toronto, Toronto, ON, Canada, ⁴Medical Biophysics, University of Toronto, Toronto, ON, Canada

Introduction: Changes in the [1-¹³C]lactate signal observed *in vivo* following injection hyperpolarized [1-¹³C]pyruvate have been shown to be a marker for early treatment response (1-2). With the emergence of hypofractionated radiation therapy (3), this tool for detecting early response to treatments non-invasively may be very important for management of certain cancers. Understanding the mechanism associated with the change in [1-¹³C]lactate signal would also be helpful for future treatment planning and development of novel therapeutic protocols. In this study, the feasibility of using hyperpolarized ¹³C metabolic imaging with [1-¹³C]pyruvate for characterization of early radiation treatment response is demonstrated in a model of breast cancer.

Methods: Hardware and agent: All studies were performed using a 3T GE MR750 scanner (GE Healthcare, Waukesha, WI). A micro-strip dual-tuned ¹H-¹³C volume coil (8 cm I.D.) was used for all experiments (Magvale, San Francisco, CA). A HyperSense DNP polarizer (Oxford Instruments, Abingdon, UK) was used to polarize the substrates. Neat [1-¹³C] pyruvic acid (Isotec, Miamisburg, OH) doped with 15mM of OX63 radical and 1mM Gd chelate (Prohance®, Bracco International) was polarized and dissolved using the established protocol (4). Tumor Model: Human breast cancer (MDA-MB-231) xenografts were established in nude rats (Harlan Laboratories, Mississauga ON) subcutaneously on their hind leg. Tumors at approximately 2cm diameter were either treated with 16 Gy radiation (8 Gy each from top and bottom of the tumor, n=6) or used as untreated control (n=7). Radiation was localized to the tumor using a lead shield. Treated tumors were scanned 96 hrs post therapy. All animals were euthanized and tumors harvested following MR scanning. MR imaging: Time resolved ¹³C metabolic imaging was performed using an EPI sequence with spectral-spatial excitation (5) with 5mm isotropic spatial resolution and 5s temporal resolution from a 3D volume that included the kidneys and tumor (8cm x 8cm x 6 cm FOV). 2ml/80mM of pre-polarized [1-¹³C]pyruvate was injected (10s injection) for each study. The data acquisition started at the beginning of the substrate injection. The effective tip angle at each time point was 60 and 9 degrees for lactate and pyruvate, respectively. Data were acquired over 60s and total (summed) lactate and pyruvate signals within the tumor and kidneys were used for analysis.

Results: Representative hyperpolarized [1-¹³C]lactate image (center) and the corresponding T₂ weighted ¹H anatomical image (left) acquired from the MDA-231 tumors *in vivo* is shown in Fig.1. The time course of the [1-¹³C]lactate and [1-¹³C]pyruvate signals from the tumor is also plotted (Fig.1 right). Excellent agreement between the ¹³C signal and the anatomical delineation of the tumor was observed. Similar to prior time resolved (but not spatially resolved) ¹³C MRS studies from tumor models (1,4), signal time courses from the tumor demonstrated the early arrival of the injected substrate and later and persistent observation of the metabolite. A significant decrease in average ¹³C lactate to pyruvate ratio (1.7 vs. 2.7, students t-test, p<0.05) in the tumors was observed for the animals treated with radiation as compared to controls (Fig. 2). This ratio was found to be slightly elevated (1.0 vs. 0.9) in kidneys of treated animals as compared to control.

Conclusions: Early and significant change in hyperpolarized [1-¹³C]lactate signal in tumors was observed after a single, large dose of radiation therapy in a human breast cancer model. The non-invasive method for probing radiation treatment response presented in this study may improve management of patients under going hypofractionated radiation therapy.

Acknowledgement: This study was supported by funding from OICR.

- References:**
1. Day SE et al. *Nat. Med.* 2007 Nov;13(11):1382-7
 2. Day SE et al. *Magn Reson Med.* 2011 Feb;65(2):557-63.
 3. Ko EC et al. *Cancer Radiother* 2011 Jun;15(3):221-9.
 4. Chen AP et al. *Magn Reson Med.* 2007 Aug;187(2):357-62.
 5. Lau AZ et al. *NMR Biomed.* 2011 Oct;24(8):988-96.

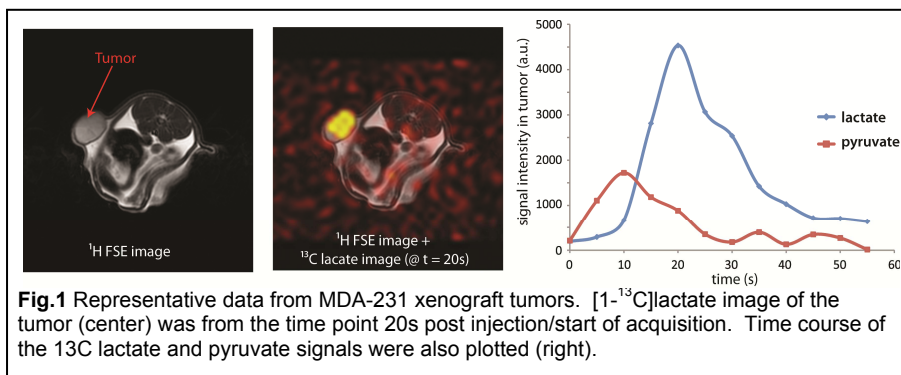


Fig.1 Representative data from MDA-231 xenograft tumors. [1-¹³C]lactate image of the tumor (center) was from the time point 20s post injection/start of acquisition. Time course of the ¹³C lactate and pyruvate signals were also plotted (right).

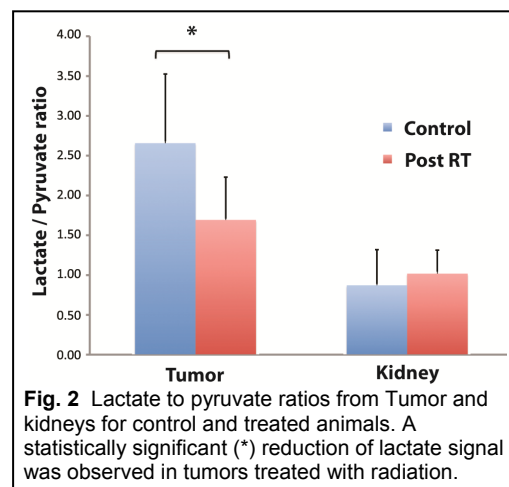


Fig. 2 Lactate to pyruvate ratios from Tumor and kidneys for control and treated animals. A statistically significant (*) reduction of lactate signal was observed in tumors treated with radiation.