

Quantitative Correlation between DCE-MRI and Broadband Diffuse Optical Spectroscopy Imaging in Breast Cancer Patients Undergoing Neoadjuvant Chemotherapy

Shanshan Xu^{1,2}, Ming-Jung Kim^{3,4}, Jeon-Hor Chen^{3,5}, Orhan Nalcioglu³, Bruce J. Tromberg^{1,2}, Enrico Gratton^{1,2}, and Min-Ying L. Su³

¹Biomedical Engineering Department, University of California, Irvine, California, United States, ²Beckman Laser Institute, Irvine, California, United States, ³Center for Functional Onco-Imaging, Department of Radiological Sciences, University of California, Irvine, California, United States, ⁴Department of Radiology, Yonsei University College of Medicine, Seoul, Korea, Republic of, ⁵Department of Radiology, China Medical University Hospital, Taichung, Taiwan

Background and purpose:

For patients diagnosed with stage 2 or higher breast cancer, neoadjuvant chemotherapy (NAC) has become a very important treatment option. It has been established that when patients can achieve pathologic complete response (pCR), or down to minimal residual tumor burden after NAC, they will have favorable prognosis. Furthermore, imaging may be applied during the course of therapy to evaluate how each individual patient's cancer is responding to different regimens. Of all breast imaging modalities, MRI is considered as the best tool for evaluating the extent of residual tumor following NAC; however MRI is relatively expensive, and most insurance will only pay for 2 MRI's, one before and one after the completion of NAC. If imaging can be performed more frequently, it will provide very useful information for evaluating the response and guiding the selection of optimal treatment protocol. Diffuse Optical Spectroscopy Imaging (DOSI) has evolved as a complementary imaging modality for diagnosis and characterization of breast cancer [1]. DOSI is a non-invasive functional imaging technique that employs near-infrared (NIR) light to quantitatively measure the concentration of NIR absorbers in tissues [2]. Taking advantage of the frequency-domain photon migration techniques, DOSI combines experimental measurements and model-based data analysis can provide the concentration of NIR absorbers, including water, lipid, and oxy-, deoxy-hemoglobin. In this study, we correlated DOSI parameters and DCE-MRI kinetic parameters obtained from breast cancer patients undergoing neoadjuvant chemotherapy. The patients were separated into 2 groups based on their pathological response, and the correlation between the patients in these 2 groups were separately analyzed, and compared.

Materials and Methods:

A total of 44 breast cancer patients were enrolled in a NAC study between May 2006 and July 2010. Of these, 18 patients (age range 28-64, mean 44 y/o) had received both MRI and DOSI imaging that met these inclusion criteria: 1) a patient has a baseline DCE-MRI evaluation and a DOSI scan before starting neoadjuvant chemotherapy; 2) MRI and the corresponding DOSI measurement were performed within 1 week range. DOSI measurements were taken from the tumor area determined by ultrasound and palpation. The concentration of NIR absorbers, including oxyhemoglobin (ctO2Hb), deoxyhemoglobin (ctHHb), oxygen saturation (stO2), water, and lipids were measured, and a 2-D image of a contrast function called the tissue optical index (TOI = [deoxyhemoglobin]/[water]/[bulk lipid]) was generated. The mean value for each parameter was calculated from a region corresponding to the tumor (based on ultrasound and the region showing elevated TOI compared to surrounding tissues-which has been previously verified as a consistent indicator of tumor location). For DCE-MRI, contrast enhancement kinetics was measured from manual placed ROI on color-coded enhancement maps, and analyzed using the standard Tofts model to calculate Ktrans and kep. Based on the pathological examination of the resected cancer after completing NAC, patients were categorized into pathological complete response (pCR, n=5) and non-pCR (n=13) groups. The DOSI and DCE-MRI parameters analyzed from the baseline and follow-up studies were compared within the pCR and non-pCR groups separately. The treatment-induced percentage changes were also analyzed.

Results:

Figure 1 shows pre-treatment tissue optical index mapping (TOI) and contrast-enhanced MR images from a pCR subject (upper) and a non-pCR subject (lower). The pCR subject has a better tumor/normal region contrast suggesting a higher metabolism and blood flow. Figure 2 demonstrates the Pearson's correlation between the tumor oxygenation parameters (O2Hb, HHb and stO2) measured by DOSI and the DCE-MRI kinetic parameters in the pCR group at baseline and follow-up studies. At baseline, there is a strong correlation for O2Hb vs. Ktrans ($r=0.97$), O2Hb vs. kep ($r=0.90$), HHb vs. Ktrans ($r=0.97$), HHb vs. kep ($r=0.89$), stO2 vs. Ktrans ($r=-0.99$), and stO2 vs. kep ($r=-0.88$), all significant with $p<0.05$. In the follow-up study, the correlation was much weaker and all non-significant. There was a marginal correlation between stO2 and Ktrans ($r=0.52$), and kep ($r=0.61$), respectively ($p<0.1$). In the non-pCR group, there was no significant correlation between any DCE-MRI and DOSI parameters at baseline or follow-up studies.

Discussion:

In the pCR group, prior to the treatment, stO2 is negatively correlated with Ktrans and kep. The results indicate that cancer with a higher vascular permeability has a lower oxygen saturation. These two features are associated with a hypoxic microenvironment in malignant lesions. As shown in Figure 2, this negative correlation was changed after chemotherapy. Since there was only 5 cancers in this group, the implication of this finding needs to be further examined. As also shown in Figure 2, both the oxyhemoglobin and deoxyhemoglobin decreased after chemotherapy, and this is more likely due to the decreased blood supply after treatment. In contrast to these finding in the pCR group, there was no correlation between DCE-MRI and DOSI parameters in the non-pCR patient group. This is an exploratory study of correlation between optical parameters and MRI kinetic parameters, stratified based on the pathological response of patients. Different findings were seen between these two groups, and whether these relationships can be used to predict therapeutic response need to be investigated in a larger study.

References: [1] Tromberg, B.J. et al. Med Phys 35, 2443-2451 (2008). [2] Cerussi, A. et al. J Biomed Opt 11, 044005 (2006).

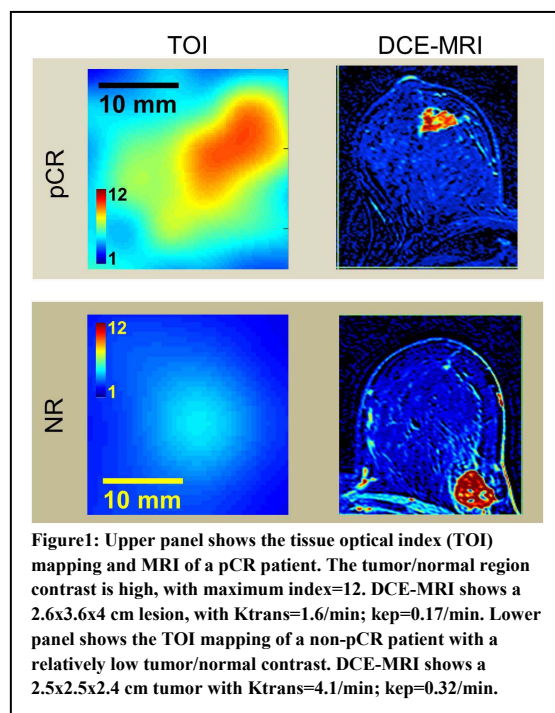


Figure 1: Upper panel shows the tissue optical index (TOI) mapping and MRI of a pCR patient. The tumor/normal region contrast is high, with maximum index=12. DCE-MRI shows a 2.6x3.6x4 cm lesion, with Ktrans=1.6/min; kep=0.17/min. Lower panel shows the TOI mapping of a non-pCR patient with a relatively low tumor/normal contrast. DCE-MRI shows a 2.5x2.5x2.4 cm tumor with Ktrans=4.1/min; kep=0.32/min.

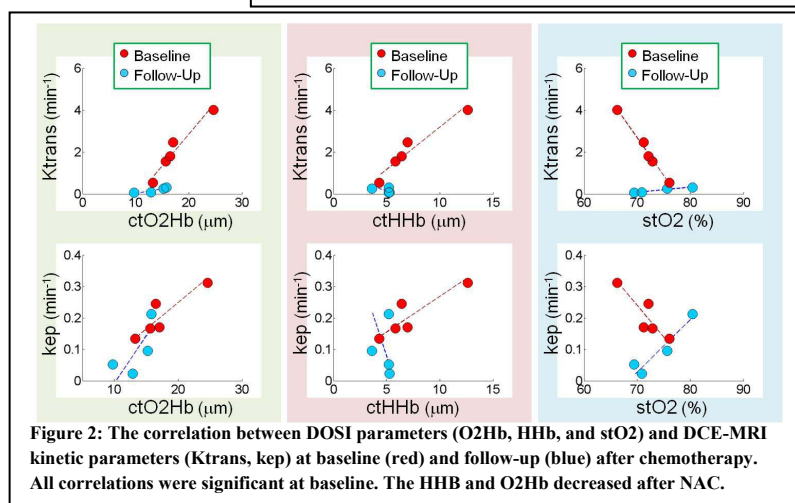


Figure 2: The correlation between DOSI parameters (O2Hb, HHb, and stO2) and DCE-MRI kinetic parameters (Ktrans, kep) at baseline (red) and follow-up (blue) after chemotherapy. All correlations were significant at baseline. The HHb and O2Hb decreased after NAC.