

# Improved Noncontact 3-Dimensional Breast MR Elastography

Jun Chen<sup>1</sup>, Roger Grimm<sup>1</sup>, Kevin Glaser<sup>1</sup>, Kugel Jennifer<sup>1</sup>, Kay Pelletier<sup>1</sup>, and Richard Ehman<sup>1</sup>  
<sup>1</sup>Radiology Department, Mayo Clinic, Rochester, MN, United States

**Introduction:** A woman born in the United States today has a 1 in 8 chance of having invasive breast cancer during her lifetime, and the risk of breast cancer increases with age and other factors [1]. It was estimated that in 2010 there will be 2 million breast cancer cases (28% being new female cancer cases), and 40,000 deaths caused by breast cancer (15% of all female deaths due to cancer) [2]. The use of screening mammography in the United States has greatly decreased breast cancer mortality since 1990, however mammography has the risk of causing overtreatment and radiation-induced breast cancer (86 cancers per 100,000 women with annual screening) [1]. Without radiation risk, contrast-enhanced (CE) MRI has high sensitivity (89-100%) for detecting malignancies, but its specificity can be as low as 30% [3]. Breast MR Elastography (MRE) is a technique for measuring the stiffness of breast tissue, which has shown promising results for differentiating malignancies from benign tissues alone or combined with breast CE-MRE[4, 5]. Previously-described drivers for breast MRE directly contact with the breast in order to transmit mechanical waves into the breast [4-8]. The contact breast drivers have the disadvantages: they add tension and distort the shape of the breasts (which may change the biomechanical properties); they have to be adjustable to accommodate differences in breast size for optimal mechanical coupling; they typically require modification of breast RF coils, limiting their use in clinical practice; and the driver device may interfere with MRI-guided breast biopsy. We have proposed a novel non-contact breast driver that avoids these problems[9]. Our hypothesis is that the non-contact breast driver design can be further optimized to improve the shear wave generation in both breasts, and that a newly developed 3D GRE acquisition based MRE sequence can be used to acquire the suitable 3D vector wave field information in 3 motion axes in both breasts simultaneously.

**Methods and Materials:** Volunteers: This study was approved by our Institutional Review Board (IRB). 6 female volunteers without known breast disease were recruited after obtaining written informed consent. Their age was 20-40 (mean: 26) years. Driver Design: The optimized noncontact breast MRE driver was designed as a narrow soft strip (3.5 X 20 X 0.8 cm), with an acoustic chamber filled with a porous air filter (Fig. 1). The breast MRE setup was described previously [9]. Each volunteer was in the prone (feet first) position with the driver in between the sternum and the bridge of a commercial breast RF coil (Liberty 9000 8-ch. breast coil, USA Instruments, Inc., Aurora, OH). MRE Sequence: A 3D GRE MRE sequence (Fig. 2) was developed to collect volumetric bilateral breast wave data on a 1.5 T scanner (GE, Wisconsin, USA) with the following parameters: mechanical frequency = 40 Hz,  $FOV_{xyz}$  = 34/34/20 cm; 2 phase offsets (quadrature sampling); motion-encoding gradient (MEG) amplitude = 2.8G/cm (tetrahedral acquisition), TR = 56.4 ms, TE = 18.1 ms (fat/water in-phase echo time); flip angle = 10°, BW = 62.5 kHz, axial imaging plane covering the whole breasts in the SI direction, acquisition matrix = 96X96X40, NEX = 1, SENSE acceleration factor = 2 (RL), total scan time = 11'19", free breathing. MRE Inversion: The vector curl of the measured wave data was calculated using 3x3x3 derivative kernels on the wrapped phase data [10]. A 3D local frequency estimation inversion was performed on the curl data with 2D directional filtering (cutoff frequencies 2 and 128 cycles/FOV) to calculate the MRE elastograms [11]. Regions of interest were drawn in glandular and adipose tissue for stiffness measurement.

**Results:** The volunteer studies demonstrated significant shear wave penetration and good visualization throughout both breasts using the improved noncontact driver and 3D GRE MRE acquisition. Fig. 3 shows MRE results from one volunteer. Fig. 3(a) is the magnitude image from the 3D GRE MRE sequence, Fig. 3(b) is the elastogram, and Fig. 3(c, d, e) are the three orthogonal components of the vector curl wave images. Fig. 4 shows box plots of stiffness values of glandular and adipose tissues in each volunteer.




Fig. 1. Non-contact soft breast MRE driver.

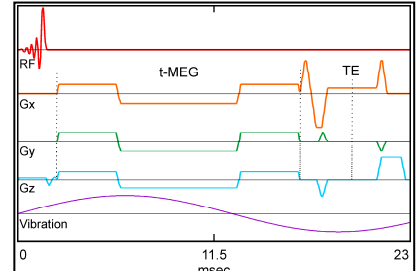


Fig. 2. Part of 3D GRE MRE for breast imaging. A dummy time (33.4 msec) after 23 msec not shown. Vibration is continuous during the whole scan (9 cycles over 4 TRs). First moment nulled MEG has a duration of 14.2 msec.

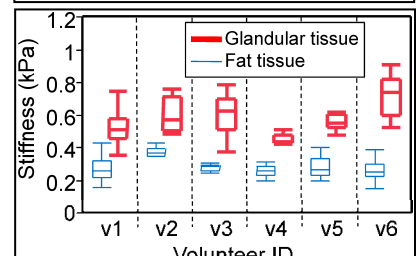


Fig. 4. Stiffness of glandular and fat tissue in the six volunteers.

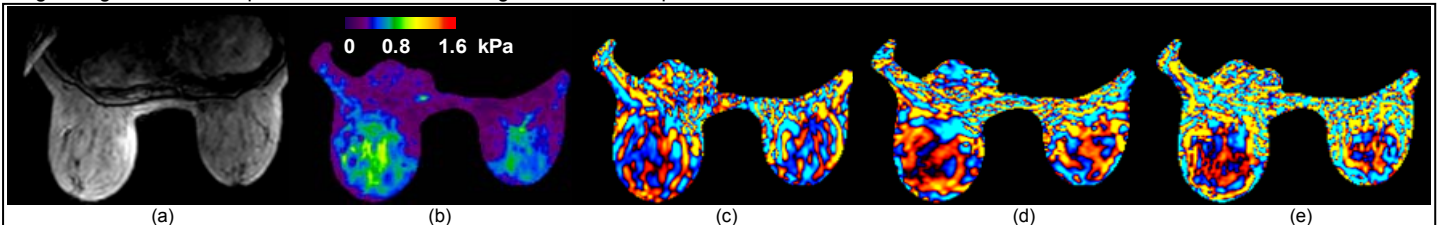


Fig. 3. MRE exam of volunteer v3. (a) Magnitude image of GREMRE. (b) Elastogram of both breasts. (c) AP, (d) RL and (e) SI axis of curl filtered shear wave field. The mean (range) stiffness of fat was 0.28(0.24 - 0.30) kPa. The mean (range) stiffness of glandular tissue was 0.61(0.37-0.79) kPa.

**Discussion:** There are two reasons for the improvements in the shear wave field generated by the new noncontact driver. First the new driver was driven at 40 Hz, which is lower than the 60-Hz frequency used in the earlier study of the noncontact driver [9]. It is well known that low-frequency waves have better soft tissue penetration than high-frequency waves. Second, the new noncontact driver is narrower than the old one (3.5 cm vs. 6.5 cm), which means less opportunity for direct contact with the breast. In this study, we did not see the stiffness overestimation of breast tissue around the driver; it was unfortunately seen in our previous study using the old wider non-contact driver, which was probably caused by the breast-driver direct contact pressure from the old wider driver [9]. The 3D GRE MRE sequence developed in this study showed significant motion in all 3 directions in both breasts. In this study we were able to use water/fat in-phase echo time (multiples of 4.5 ms at 1.5T) for the 3D GRE MRE sequence to overcome the water/fat chemical shift; while in our previous study using EPI MRE sequence, we had to run the EPI MRE sequence twice at water and fat resonance frequencies respectively. In summary, the noncontact driver is compatible with the commercial breast RF coil and can generate suitable 3D wave fields in the breasts, which can be imaged and calculated by the proposed the 3D MRE sequence and inversion. These results will motivate future studies using these techniques investigating the potential value of MRE for the assessment of breast cancer. **Acknowledgements:** NIH Grant EB01981.

**References:** [1]. Warner, E., N Engl J Med, 2011. 365(11): p. 1025-32. [2]. Jemal, A., et al., 2010. CA Cancer J Clin. 60(5): p. 277-300. [3]. Kuhl, C., Radiology, 2007. 244(2): p. 356-378. [4]. Siegmann, K.C., et al., Eur Radiol, 2010. 20(2): p. 318-25. [5]. McKnight, A.L., et al., AJR Am J Roentgenol, 2002. 178(6): p. 1411-7. [6]. Van Houten, E.E., et al., JMRI, 2003. 17(1): p. 72-85. [7]. Sinkus, R., et al., MRM, 2007. 58(6): p. 1135-44. [8]. Plewes, D.B., et al., Phys Med Biol, 2000. 45(6): p. 1591-610. [9]. Chen, J., et al., ISMRM proceedings 2011, 3490. [10]. Glaser, K.J., ISMRM 4669., 2009. [11]. Manduca, A., et al., Med Image Anal, 2001. 5(4): p. 237-54.