

# Changes in Resting Connectivity between Functional Networks in a Patient with Significant Recovery from Complete Cervical Spinal Cord Injury

Ann S Choe<sup>1,2</sup>, Visar Belegu<sup>1,2</sup>, Cristina Sadowsky<sup>2,3</sup>, Peter C van Zijl<sup>4,5</sup>, James Pekar<sup>4,5</sup>, and John McDonald<sup>1,2</sup>

<sup>1</sup>Department of Neurology, Johns Hopkins University School of Medicine, Baltimore, MD, United States, <sup>2</sup>International Center for Spinal Cord Injury, Hugo Moser Research Institute at Kennedy Krieger Inc, Baltimore, MD, United States, <sup>3</sup>Physical Medicine and Rehabilitation, Johns Hopkins University School of Medicine, Baltimore, MD, United States, <sup>4</sup>Russell H. Morgan Department of Radiology and Radiological Science, Johns Hopkins University School of Medicine, Baltimore, MD, United States, <sup>5</sup>F.M. Kirby Research Center for Functional Brain Imaging, Kennedy Krieger Institute, Baltimore, MD, United States

**Introduction** Can MRI inform classification of spinal cord injury (SCI), and assess brain changes resulting from that injury? MRI-based evaluation of SCI is needed for better diagnosis of the severity of SCI as well as for monitoring and optimizing therapies for subjects with SCI. While traditional MR methods such as T2-weighted imaging provide anatomical information about the injury (1), such information lacks specificity and is insufficient for prognostication purposes. In this study, we used advanced MR methods to report on the structural and functional alterations in the central nervous system of a patient who recovered significant neurological function after SCI. Structural integrity of the spinal cord was evaluated using DTI and magnetization transfer imaging (MT). In addition, changes in connectivity between different functional networks were evaluated using resting state fMRI (rs-fMRI) to investigate whether it can be used to assess functional changes in subjects with SCIs.

**Methods** The subject suffered complete paralysis below the cervical C4 level in 1974. In 2007, reevaluation of his injury showed that he recovered to an ASIA D (American Spinal Injury Association scale; least severe) injury. He regained 94% of motor function back in upper body and 100% in lower body. He gained 24% of sensory function back in lower body.

Ten healthy controls were recruited for spinal cord imaging. DTI (multi-slice, pulse gradient spin echo,  $b = 0, 500 \text{ s/mm}^2$ , 16 directions,  $1.5 \times 1.5 \times 3 \text{ mm}^3$ , 3 acquisitions with 2 min/acq) and MT (3D spoiled gradient-echo with multi-shot EPI readout,  $0.61 \times 0.69 \times 3 \text{ mm}^3$ , 8 min/acq) images were acquired. Major spinal columns were delineated using diffusion fiber tractography, which enabled tract-specific data comparisons. Data from twenty controls from a previously acquired dataset (2) were used as controls for the brain resting state functional imaging (420 sec/runs, single-shot SENSE-EPI,  $3 \text{ mm}^3$  isotropic). The subject was imaged using the imaging parameters in ref (2) and a total of 8 runs were performed. Functional independent components were estimated using group independent component analysis (3). Connectivity between pairs of the components was measured using between network connectivity (BNC) correlations (4).

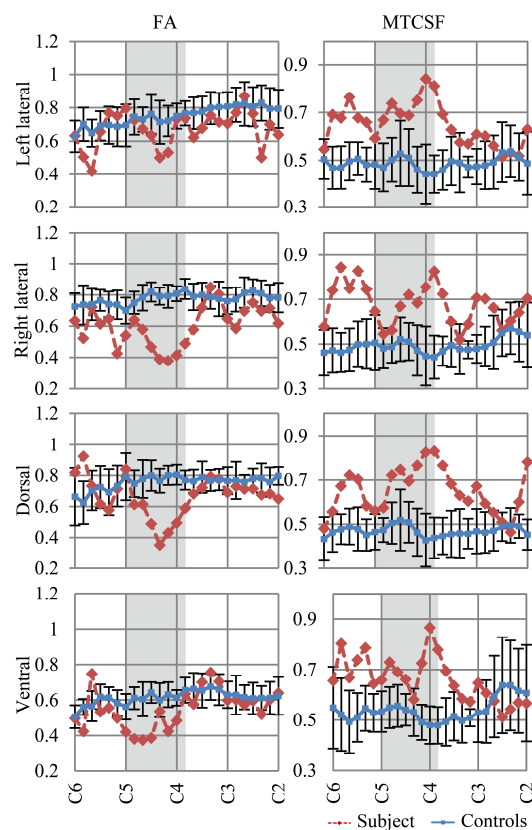
**Results/Discussion** The parameter profiles (Figure 1) span the length of cervical cord from C2 to C6. Gray boxes represent the injury epicenter of the SCI subject. Fractional anisotropy (FA) and MTCSF (MT normalized by cerebrospinal fluid) values of controls (blue lines) stay relatively constant. FA decreased by more than a standard deviation (std) at the injury epicenter in all spinal columns, with the greatest decrease occurring in the dorsal column. Changes in FA were bigger in the right lateral column than those in the left lateral column. These observations are consistent with the subject's ASIA motor and sensory evaluations, as the subject's sensory deficit is worse than motor deficit and has worse motor ability on the right side of the body compared to left. MTCSF increased by more than one std at the injury epicenter in all spinal columns. Unlike FA, which showed sharp changes mostly at the injury epicenter, MTCSF changes occurred throughout the cervical cord.

Connectivity between pairs of functional networks was visualized using between network connectivity (BNC) correlation matrices. Figure 2(A) shows a combined correlation matrix, where in reference to the top-left to bottom-right diagonal axis, bottom left portion corresponds to the correlation matrix of the controls and top right portion corresponds to the correlation matrix of the subject. Figure 2(B) shows the result of a univariate analysis. Compared to the BNC of the controls, BNC of the subject showed: 1) increased connectivity between the sensorimotor and the visual network, 2) decreased connectivity between the auditory network and the rest of the functional networks. The patient has not regained sensory function in the lower body and relies heavily on vision to guide his movements, such as walking. The increased connectivity between the sensorimotor and the visual networks is consistent with this clinical presentation and suggests compensatory functional changes in the subject's brain. Also, it was discovered after data analysis that the patient has auditory deficiencies, which explains the decreased auditory network connectivity shown in Figure 2.

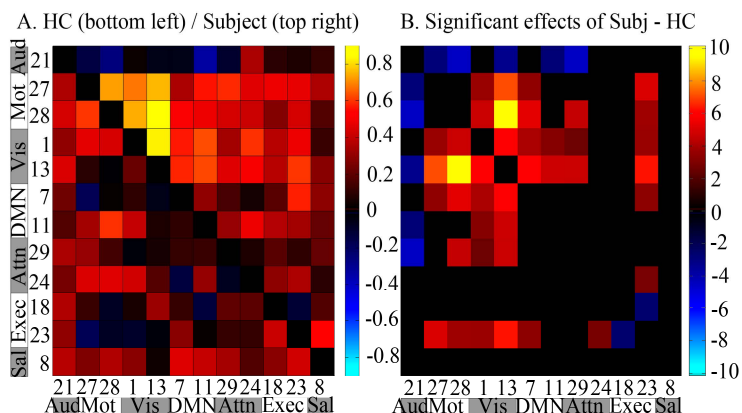
**Conclusion** Recovery from ASIA A injury is extremely rare, with 94% of patients with level A injury failing to improve neurologically at the time of their discharge (5). DTI, MT, and rs-fMRI provided a unique set of tools to observe the current structural and functional state of a patient who made a remarkable recovery from his ASIA A injury. Pattern of changes in the DTI and MT-derived parameters in the cord was consistent with the subject's motor and sensory function evaluations, and the changes in the BNC of the subject was consistent with the subject's clinical presentation, suggesting that rs-fMRI can be used to observe brain functional changes of SCI subjects.

**Acknowledgements** This work was supported in part by grants from the DOD (W81XWH-08-1-0192) and NIH (R21 EB006120-01A2 and P41 RR015241). The authors would like to thank Dr. Suresh Joel for his help with rs-fMRI data analysis.

**References** [1] Ramon S. Spinal Cord 1997;35(10):664-73. [2] Landman BA. Neuroimage 2011;54(4):2854-66. [3] Calhoun VD. Hum Brain Mapp 2001;14(3):140-51. [4] Joel SE. Magn Reson Med 2011;66(3):644-57. [5] Vazquez XM. J Forensic Leg Med 2008;15(1):20-3.



**Figure 1.** Structural integrity of the cervical cord was evaluated using FA and MTCSF. Each plot represents parameter profiles along the major cervical spinal columns.



**Figure 2.** (A) Combined BNC correlation matrix shows synchrony between pairs of functional networks. (B) Result of a univariate regression analysis confirms differences in the controls' and the subject's BNC correlations. (Aud: auditory, Mot: motor, Vis: visual, DMN: default mode network, Attn: attention, Exec: executive, Sal: salience)