

Retinal and Choroidal Blood Flow Autoregulation in Rats at 11.7T

Guang Li¹, Yen-Yu I. Shih², Bryan H. De La Garza², Jeffrey W. Kiel^{3,4}, and Timothy Q. Duong²

¹Radiology, University of Texas Health Science Center at San Antonio, San Antonio, TX, United States, ²Research Imaging Institute, University of Texas Health Science Center at San Antonio, San Antonio, TX, United States, ³Ophthalmology, University of Texas Health Science Center at San Antonio, San Antonio, TX, United States, ⁴Physiology, University of Texas Health Science Center at San Antonio, San Antonio, TX, United States

Introduction: Autoregulation of ocular blood flow (BF) with respect to changing blood pressure (BP) is important to retinal health. Autoregulation dysfunction has been implicated in many retinal diseases such as glaucoma [1]. BF to the retina is supplied by two separate circulations: the retinal and choroidal vasculatures, which are regulated very differently. They may respond differently to BP changes. In contrast to classic optically based techniques, MRI provides depth-resolved physiological (i.e., BF and) and functional information non-invasively in the retina with laminar resolution and a large FOV [2].

This study employed very high resolution BF MRI ($47 \times 47 \mu\text{m}^2$) to investigate the retinal and choroidal BF autoregulation during acute hypertension. BP was elevated by transient occlusion of the descending aorta. Retinal and choroidal BF (RBF and ChBF) MRI as well as retinal and choroidal BOLD (RBOLD and ChBOLD) MRI were simultaneously measured continuously during baseline and acute hypertension period.

Method: 6 Long-Evans rats were used for imaging and 3 for blood gas measurements. Anesthesia was maintained at 1.1% isoflurane. The rats were paralyzed with pancuronium bromide (4 mg/kg first dose, 4 mg/kg/hr, i.p.) and mechanically ventilated. Systemic BP was continuously monitored through a PE-50 tube cannulating into right axillary artery. Arterial blood was sampled through the same PE50. End-tidal CO_2 , SO_2 , heart rate (HR), and rectal temperature were maintained within normal ranges. BP was modulated by a balloon catheter placed in the descending aorta (near the diaphragm) inserted via the right femoral artery. The BP was elevated by 10-70 mmHg from baseline through partially or completely redirecting blood from lower body to upper body.

The experiment was conducted on an 11.7 T Bruker Biospec using a surface coil with active decoupling (ID=1 cm) and a separated butterfly neck coil for continuous arterial spin labeling (cASL). BF MRI of a single axial slice bisecting the optic nerve was acquired using 4-segment gradient-echo (GE) inversion-recovery (IR) EPI+cASL with $\text{FOV}=7 \times 7 \text{ mm}^2$, $\text{TR/TE/TI}=4000/12.8/2100 \text{ ms}$, $\text{resolution}=47 \times 47 \times 1000 \mu\text{m}^3$. Labeling duration is the same as TI. IR pulse was used to suppress vitreous signals to improve sensitivity. M_0 images were acquired using GE EPI ($\text{TR/TE}=10000/12.8 \text{ ms}$) with the same geometry. Modulation paradigm was OFF-ON. The OFF period (320sec, 10-pair non- and labeled images) was baseline and the ON period (320sec, 10-pair images) was BP elevation period. BF profiles across the retinal thickness were obtained by Matlab [3]. The mean BF peak values of the retinal and choroidal vascular layers were tabulated. BOLD data were extracted from non-labeled images and their time courses were detrended [4]. Multiple trails were performed on each rat with 10–15 min break between consecutive trails. Total 20 trails were performed on 6 rats.

Results: Arterial pO_2 and pH increased and pCO_2 decreased significantly during BP elevation (Table 1). Fig 1 shows a typical trace of BP, and group mean traces of ChBF, RBF, ChBOLD and RBOLD associated with the balloon occlusion. BP, ChBOLD and RBOLD were elevated and maintained stable during the BP elevation period. During this period, ChBF increased initially but declined slowly toward baseline, while RBF did not have obvious changes. Fig 2A shows that ΔRBF due to ΔBP (median= 0.08 ml/g/min) was not significantly different from 0 ($p=0.47$), but ΔChBF (median= 1.7 ml/g/min) was ($p=0.001$). The slopes of ΔBF vs. ΔBP in both circulations (Fig 2B&C) were not significantly different from 0 ($p=0.39 \& 0.32$), which indicate the absence of correlation between RBF/ChBF and BP. Fig 3A shows that both %RBOLD (median= 7.2%) and %ChBOLD (median= 14.6%) were significantly larger than 0 ($p<0.001$). Fig 3B shows %ChBOLD was correlated to %BF ($p=0.002$). Fig 3C shows %RBOLD and %ChBOLD were linearly correlated ($p=0.001$).

Discussion & Conclusion: Retinal BF autoregulation was detected since ΔRBF did not change during the BP elevation period. Choroidal BF autoregulation was also detected as indicated by the absence of correlation between ΔChBF and ΔBP . The offset of 1.7 ml/g/min in ChBF was because the reported BF was averaged over the duration of BP elevation where BF increased initially and slowly returning to baseline. It is also possible that choroidal BF autoregulation established a new and higher ChBF. The offset in Fig 2B and the slow return toward baseline in Fig 1 could be due to isoflurane which is a vasodilator and has a dose-dependent effect on BF autoregulation [5]. Our results are consistent with other studies which detected retinal [6] and choroidal [7] BF autoregulation.

%BOLD increased positively in both circulations, and %ChBOLD was linearly correlated to ChBF and %RBOLD, in spite of no detected changes in RBF. The increased BOLD signal could be because of decreased oxygen extraction fraction and/or increased blood pO_2 increases. Blood gases showed increased arterial pO_2 which is likely due to the increased pulmonary perfusion caused by elevated BP.

In conclusion, we developed a model of acute hypertension in rat for use in the MRI scanner. We found that retinal and choroidal BF are tightly autoregulated under isoflurane anesthesia in rat. This approach sets the stage for study of retinal diseases (such as glaucoma and diabetic retinopathy) in which autoregulation may be perturbed.

Reference 1) Risner et al. J Glaucoma. 2009;18(6):429. 2) Duong et al, NMR Biomedicine, 2008; 21: 978. 3) Li et al. IOVS 2009, 50:1824. 4) Cook et al. The Holocene 1997 7:361. 5) Hoffman et al, Anesth Analg, 1991 73:753. 6) Robinson et al. IVOS 1986;27(5):722. 7) Kiel, exp. Eye Res., 1994, 58:529.

Table 1. Blood gas measurements (*: p-value < 0.05, Wilcoxon rank-sum test)

| | pCO_2 | pO_2 | pH |
|--------------|------------------|-------------------|--------------------|
| Baseline | 41.7 ± 2.1 | 132 ± 7.5 | 7.39 ± 0.055 |
| BP elevation | $32.6 \pm 3.9^*$ | $157.1 \pm 9.5^*$ | $7.49 \pm 0.039^*$ |

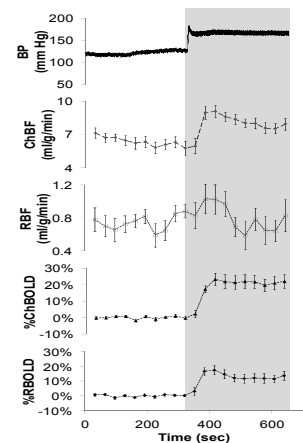


Fig 1. A typical trace of BP, and group mean traces of ChBF, RBF, ChBOLD and RBOLD. Occlusion duration is indicated by the shaded area

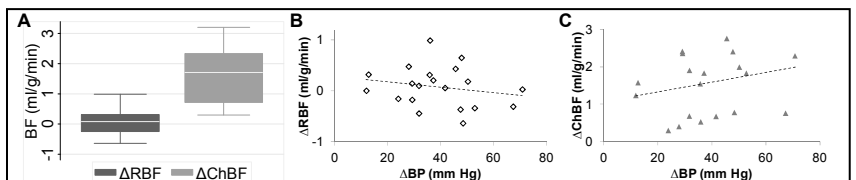


Fig 2. (A) Medians of ΔRBF and ΔChBF due to ΔBP were 0.08 and 1.7 ml/g/min , and the median of ΔRBF was not significantly different from 0 ($p=0.47$) but the median of ΔChBF was ($p=0.001$). This means RBF did not change but ChBF increased by an offset of 1.7 ml/g/min . (B)&(C) ΔRBF & ΔChBF vs. ΔBP : The slopes of the trend lines were not significantly different from 0 ($p=0.39$ and 0.32). Therefore, BF was not correlated with BP, which indicates retinal and choroidal BF autoregulation.

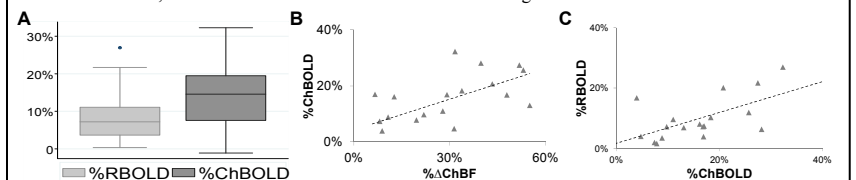


Fig 3. (A) %RBOLD (median= 7.2%) and %ChBOLD (median= 14.6%) were significantly larger than 0 ($p<0.001$). (B) %ChBOLD is linearly increase with %ChBF ($p=0.002$). (C) %RBOLD are linearly correlated with %ChBOLD ($p=0.001$).