

Evaluation of pseudocontinuous arterial spin labeling in moyamoya patients: comparison with CT perfusion

Songlin Yu¹, Rui Wang², Dong Zhang³, Rong Wang³, Shuo Wang³, Zhentao Zuo², Lin Ai⁴, Bo Wang², Danny J. J. Wang⁵, and Jizong Zhao³

¹Beijing Tiantan Hospital, Capital Medical University, Beijing, China, People's Republic of, ²The State Key Laboratory of Brain and Cognitive Science, Institute of Biophysics, Chinese Academy of, ³Beijing Tiantan Hospital, Capital Medical University, ⁴Beijing Neurosurgical Institute, ⁵Department of Neurology, University of California Los Angeles Ahmanson-Lovelace Brain Mapping Center

Introduction:

Moyamoya disease is characterized by the progressive stenosis or occlusion of terminal ICAs. Such patient is usually evaluated by both digital subtraction angiography (DSA) and techniques that can evaluate cerebral hemodynamics before making decisions on corresponding therapeutic strategies in clinical practice. Arterial spin labeling (ASL) is emerging as such a technique. It is entirely non-invasive using magnetically labeled water as an endogenous tracer. However, the disadvantage is the delayed arterial transit times (ATT) through collateral pathways which may cause a significant underestimation of CBF. In this work, we performed pseudocontinuous ASL (pCASL) with four postlabel delay (PLD) times and correlated the CBF result with that of CT perfusion to determine the optimal PLD that can best reflect the hemodynamics in moyamoya patients.

Methods:

Six patients diagnosed as moyamoya disease were included in this study. Both CT perfusion (CTP) and pCASL were examined in each patient. CTP was performed on 16-section CT scanners (Somatom Volume Zoom; Siemens, Erlangen, Germany). Four contiguous sections with a slice thickness of 5 mm from the level of the basal ganglia/internal capsules to the upper portion of the lateral ventricles were obtained. The MR sequences were performed on 3T Siemens Trio Tim System using body coil transmitter and 12-channel head coil as receiver. The patients were scanned using pCASL with background suppressed (BS) 3D GRASE sequence (1). Imaging parameters were as follows: TR/TE=3.5s/22.62ms, PLD=1.5/2/2.5/3s, label offset=90mm, voxel size=3.44x3.44x5mm³, 26 slices covering whole brain with total scan time=9.4min (4 PLDs). A M0 image was acquired using TR=5s and PLD=4s. In addition, high resolution sagittal T1 MPRAGE image was acquired for coregistration. MR and CT images were co-registered and the MR CBF maps were re-sliced to the space of CT perfusion maps. CBF of each hemisphere of every section was calculated by both CTP and pCASL. Finally, Pearson correlation coefficient between the two modality was calculated.

Results:

Quantitative data of rCBF from 6 patients for both CTP and pCASL were successfully obtained. Visually, the brain territories showing abnormal perfusion can be clearly identified on the four pCASL images with different PLDs. The average values of CBF obtained from CTP and pCASL (1500 to 3000ms) are 36.49, 41.47, 41.69, 42.80, 40.04 ml/100g/min respectively (Fig. 1). pCASL CBF is significantly higher than that from CTP ($p=0.004$). But there are no differences between the four pCASL measurements with different PLDs. The Pearson correlation coefficients between CTP and pCASL (1500 to 3000ms) are 0.402 ($P=0.005$), 0.557 ($P<0.001$), 0.551 ($P<0.001$) and 0.484 ($P<0.001$) respectively which indicates pCASL with 2000 to 2500ms PLD is best correlated with CTP.

Discussion: The major quantitative calculation error of rCBF using ASL may exist in the differences in arterial transit arrival time. In this study we used pCASL with four PLDs to investigate the best delay time that correlates with CTP which is widely used in clinical practice. The results show that pCASL images obtained at 2 to 2.5s best correlate with CTP. CBF values obtained at 1.5s may underestimate CBF values while the values obtained at 3000ms begin to decrease, likely due to the relaxation of the labeled signal.

Reference: [1] Fernández-Seara, MA. et al., Magn Reson Med, 54(5):1241-1247, 2005.

Acknowledgements: This work is supported by National Natural Science Foundation of China of Tiantan Hospital (30830101) and MOST 2005CB522800, NSFC 30621004, and CAS KSCX2-YW-R-259.

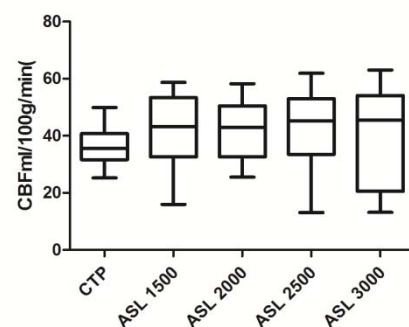


Fig 1. Boxplot of quantitative data of rCBF

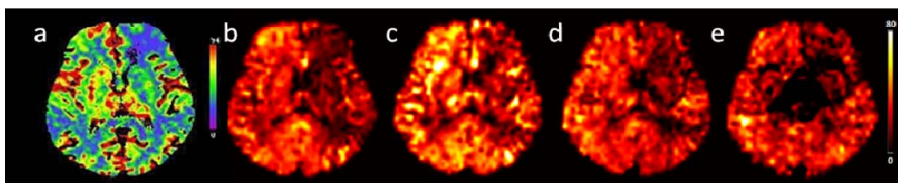


Fig 2. One patient diagnosed as moyamoya disease. CTP CBF map (a) shows abnormal perfusion in left frontal and right temporal lobes. ASL 1500ms (b) shows enlarged abnormal perfusion territory. While ASL 2000ms (c) and 2500ms (d) correlate well with CTP image. The disparity between ASL 1500ms and ASL 2000ms may due to the occlusion of left internal carotid artery and right middle carotid artery and formed collateral circulation which were confirmed by DSA.