

Functional diffusion maps (fDMs) in glioblastoma treated with dendritic cell therapy.

Robert J. Harris^{1,2}, Robert M. Prins³, Whitney B. Pope¹, Timothy M. Cloughesy⁴, Linda M. Liao³, and Benjamin M. Ellingson^{1,2}

¹Radiological Sciences, David Geffen School of Medicine, University of California - Los Angeles, Los Angeles, CA, United States, ²Biomedical Physics, David Geffen School of Medicine, University of California - Los Angeles, Los Angeles, CA, United States, ³Neurosurgery, David Geffen School of Medicine, University of California - Los Angeles, Los Angeles, CA, United States, ⁴Neurology, David Geffen School of Medicine, University of California - Los Angeles, Los Angeles, CA, United States

Introduction

Dendritic cells have long been regarded as the most potent antigen-presenting cells in the immune system. Once activated, they function by interacting with T-cells and B-cells to shape an adaptive immune response. The study of dendritic cell activity has been a region of many important developments in the last several years, including the 2011 Nobel Prize in Physiology or Medicine. Glioblastoma multiforme (GBM) is a particular type of infiltrative malignant tumor that is trademarked by a very poor patient prognosis. Recent attention has been given to dendritic cell vaccines as a novel therapy for human brain tumors. Dendritic cell therapy (DC) involves loading a dendritic cell with antigens, specifically those found on glioma cells, to induce a T cell mediated anti-tumor response. To our knowledge, no studies have examined diffusion weighted MRI, or functional diffusion maps (fDMs), in GBM patient response to DC therapy. fDMs have shown utility as a biomarker in human glioma and GBM¹, and diffusion MRI in general is regarded as a highly useful tool for extracting information unavailable in conventional anatomical MRI. We hypothesize fDMs may serve as a quantitative biomarker for the efficacy of DC therapy, providing insight into tumor growth characteristics independent of standard MR changes. In the current study, we examined ten patients and quantified serial changes in fDMs along with volumetric changes in tumor before and after DC therapy.

Methods

A total of 10 patients were selected retrospectively from our Neuro-Oncology database. Inclusion criteria included pathology confirmed GBM based on MRI and clinical data, along with reasonable quality diffusion and anatomical data at time points before and after dendritic cell therapy. Data was collected on a 1.5T or 3T Siemens or GE system (UCLA, Los Angeles, CA) using standard clinical pulse sequences. Along with anatomical data, either diffusion weighted images (DWIs) or diffusion tensor images (DTIs) were collected with TE/TR=70-120ms/7000-10000ms or TE/TR=86ms/10400ms (12 directions), respectively. ADC was calculated from either b=0 and b=1000 s/mm² images for DWIs, or from averaging the 12 directional DWIs from from DTI datasets. All images for each patient were registered to a high-resolution (1.0 mm isotropic), T1-weighted brain atlas (MNI152) using a mutual information algorithm and a 12-degree of freedom transformation using FSL (FMRIB, Oxford, UK). A manual registration step was then performed on the diffusion data to enhance voxel-wise alignment. fDMs were computed using voxel-wise subtraction maps of ADC data from the first available time point, as defined in previously established methods, where changes in diffusion relative to baseline are classified based on whether they are significantly increasing, significantly decreasing, or have no significant change. Regions of interest were created by masking FLAIR and contrast-enhancing lesions on the time point prior to treatment with the most pronounced lesion volume. These masks were used to calculate the volume of significantly decreasing (blue) and significantly increasing (red) fDM volumes in the lesion.

Results

Of all ten patients studied, only a single patient had a partial response (PR) according to RANO criterion; whereas, all other patients evaluated had either stable disease (SD) or were radiographic non-responders (NR). The patient showing a clear PR based on FLAIR and contrast-enhancing volumes for multiple time points after treatment showed an initial increase in volume of tissue having a decrease in ADC (blue regions) immediately after injection (green region and arrows), then the volume of tissue having a decrease in ADC systematically decreased over time. Similarly, the volume of tissue with an increase in ADC (red voxels) increased over time in response to DC therapy, suggesting an anti-tumoral response to DC treatment. In contrast, two patients showing a non-response based on the same criteria showed a steady increase in blue fDM volume following treatment. One patient showed a clear increase in tumor volume corresponding with an increase in the volume of tissue with decreased ADC (blue voxels). A second patient showed only a slight increase in contrast-enhancing or FLAIR volume during progression, whereas the volume of tissue with decreased ADC (blue voxels) were steadily increasing. The fDM volumes for this patient did not appear to change as a result of DC therapy.

Discussion

In general, the FLAIR mask volumes were more useful when calculating fDMs, as contrast-enhanced images often had small tumor volumes making fDMs difficult to interpret. fDM trends in the current study support the hypothesis that a steadily decreasing volume of tissue with decreased ADC (blue voxels), combined with a steadily increasing volume of tissue with increased ADC (red voxels) following DC therapy suggests a relatively favorable response. This response is likely due to an increase in the cytotoxic activity of the DC antigens impacting local sites of tumor. Alternatively, data from the current study suggests steadily increasing volume of tissue with decreased ADC (blue voxels) is indicative of failed therapy and suggests progressively growing hypercellular tumor. Future studies with a larger patient population, more time points and uniform acquisition sequences is warranted to verify these observations.

1) Ellingson BM, Validation of functional diffusion maps (fDMs) as a biomarker for human glioma cellularity, JMIR 2010.

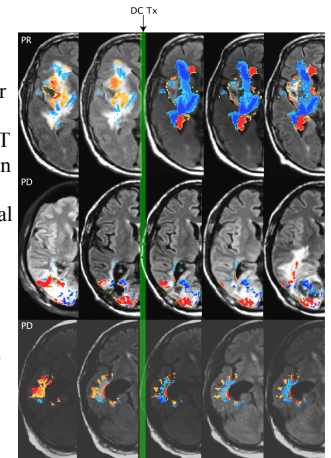


Figure 1: FDM results for patients on dendritic cell therapy. Top patient had a partial response (PR) and the bottom two patients had progressive disease (PD).

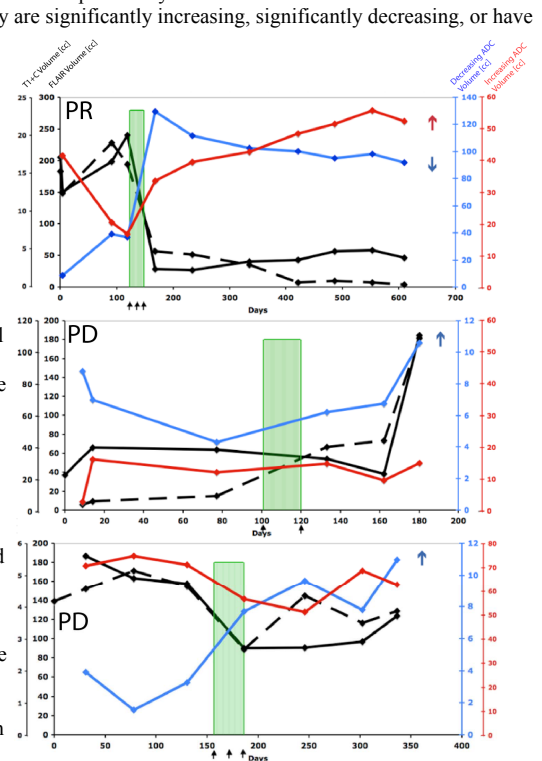


Figure 2: Lesion volume and fDM trends for the three DC therapy patients. Solid black (inner left axis) represents FLAIR volume, dashed black (outer left axis) represents contrast-enhancing volume, blue represents volume of tissue with decreasing ADC (in FLAIR mask), red represents volume of tissue with increasing ADC. PR = Partial Response, PD = Progressive Disease. Black arrows signify dendritic injection dates.