

Age and breast density dependence of choline in breasts of healthy female subjects found using 3D-MRSI

Lenka Minarikova¹, Wolfgang Bogner¹, Marek Chmelik¹, Katja Pinker-Domenig¹, Hubert Bickel¹, Thomas Helbich¹, Siegfried Trattnig¹, and Stephan Gruber¹
¹Centre of Excellence HF MR, Department of Radiology, Medical University of Vienna, Vienna, Austria

Introduction:

In several studies it was shown that MR-spectroscopy (MRS) is an important tool to distinguish between benign and malignant breast lesions with high sensitivity and specificity [1, 2]. One false positive finding in a benign lesions of a healthy female subject (24 yo) motivated us to apply three-dimensional spectroscopic imaging (3D-MRSI) at 3 T in a group of healthy females in the age range of 20-38 yo to test if the concentration of choline (Cho) is depending on other factors than malignancy (age, breast density).

Material and Methods

32 healthy female volunteers (age range 20-38) were successfully measured on a 3T system (Siemens Tim Trio, Erlangen, Germany) using a four-channel breast coil. After performing a standard imaging protocol including high-spatial-resolution T1-VIBE, 3D-MRSI and Dixon imaging was applied. For 3D-MRSI a sequence with PRESS preselection, weak water suppression, spectral fat and spatial outer volume suppression was used for all measurements (TR/TE = 1180/135ms, scan time 11 min 38 sec, FOV 12 × 12 × 12 cm³ and 12 × 12 × 12 phase encoding steps, voxel size = 1 cm³, 100% hamming-filter and 2 averages per measurement). Before processing, the data were zero filled to 16 × 16 × 16 voxels. Cho-containing voxels were processed to obtain the signal-to-noise ratios (SNR) for all spectra in which Cho was detectable. The Dixon image was acquired with 352 × 352 × 192 isotropic resolution (1 voxel ≈ 1 mm³). Breast density, calculated as number of water/all voxels in PRESS box voxels volume in Dixon images, and mean Cho SNR (as the average of Cho SNR from all voxels inside the PRESS box) were determined using MATLAB[®] software (MathWorks).

Results: In healthy female subjects scheduled for this study, Cho was detected in a large fraction of the breast tissue. The means of choline SNRs were showing an exponential regression correlation ($R^2 = 0.61$) with breast density (fig. 1). Cho was more likely detectable in breast tissue of younger subjects (see Figure 2). SNR means ranged from 0.22 to 5.47 (average: 1.50 ± 1.20).

Conclusion

In this pilot study we report, that Cho signal in breasts of healthy female subjects can be detected with high SNR in a large fraction of the normal breast tissue and the SNRs show an exponential correlation with breast density. There is different age distribution in the group with Cho signal than in the group without visible Cho in breast tissue. In previous studies, using single-voxel MRS or multivoxel MRSI, Cho signal with SNR > 2.6 was defined as a marker of malignancy in breast lesions [1]. In some healthy females the SNR of Cho is comparable or higher than SNRs of Cho reported in malignant breast lesions. Benign and malignant lesions in young women are rare. However, breast MRS-data from younger subjects with breast lesions should be interpreted with caution.

Clinical Relevance

These results indicate, that the specificity and sensitivity of MRS to distinguish between benign and malignant breast lesions is reduced in young patients if age/density dependence is not taken into account. Therefore, spectroscopy should be used with the foreknowledge of possible false positive results in a multiparametric clinical MR-measurement protocol in younger female patients for breast cancer diagnosis.

References:

1. Gruber S, Debski BK, Pinker K, Chmelik M, Grabner G, Helbich T, Trattnig S, Bogner W: **Three-dimensional Proton MR Spectroscopic Imaging at 3 T for the Differentiation of Benign and Malignant Breast Lesions.** *Radiology* 2011,
2. Bolan PJ, Nelson MT, Yee D, Garwood M: **Imaging in breast cancer: Magnetic resonance spectroscopy.** *Breast_Cancer Res.* 2005;7(4):149-52

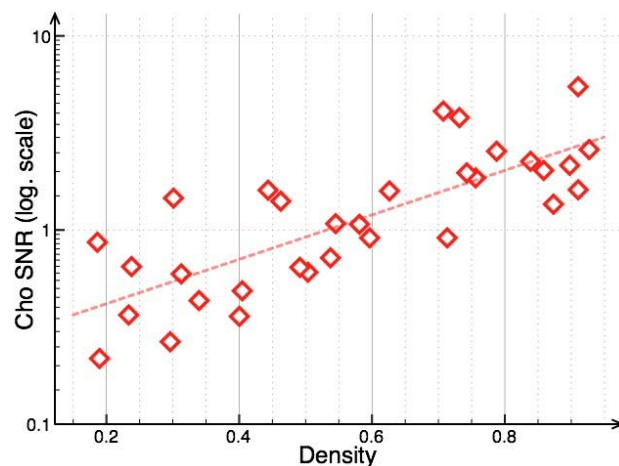


Figure 1: Means of choline signal in different volunteers in correlation with breast density.

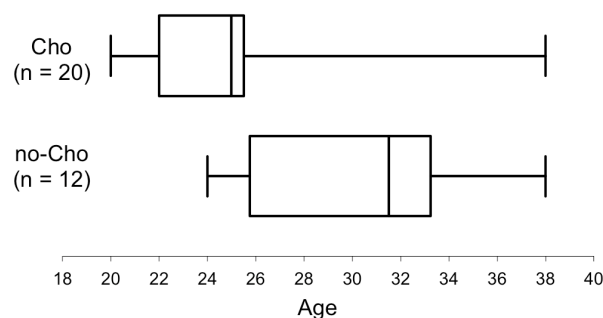


Figure 2: Boxplot: significantly different age distribution of Cho occurrence in breast tissue ($P = 0.0033$, $\alpha = 0.05$).