

# Changes in breast tumor perfusion during neoadjuvant chemotherapy: quantitative MRI in a clinical protocol

David A. Broadbent<sup>1</sup>, Daniel J. Wilson<sup>1</sup>, Nisha Sharma<sup>2</sup>, Barbara J. Dall<sup>2</sup>, Sarah E. Bacon<sup>1</sup>, Steven P. Sourbron<sup>3</sup>, and David L. Buckley<sup>3</sup>

<sup>1</sup>Medical Physics & Engineering, Leeds Teaching Hospitals NHS Trust, Leeds, West Yorkshire, United Kingdom, <sup>2</sup>Radiology, Leeds Teaching Hospitals NHS Trust, Leeds, West Yorkshire, United Kingdom, <sup>3</sup>Division of Medical Physics, University of Leeds, Leeds, West Yorkshire, United Kingdom

**Introduction.** Numerous studies have shown dynamic contrast-enhanced (DCE) MRI to be a useful biomarker of response to neoadjuvant chemotherapy (NAC) in breast cancer and several of these studies have reported the use of quantitative parameters such as  $K^{\text{trans}}$  to measure response [1-3]. However, despite the fact that MRI has been shown capable of measuring absolute values of physiological parameters such as tumor perfusion and capillary permeability in the work-up of breast cancer [4,5], no MRI studies have yet reported such parameters in the treatment setting. 15-O H<sub>2</sub>O PET has been used to demonstrate changes in tumor perfusion in response to NAC [6], but is not a practical tool for routine monitoring of such patients. In this study we have introduced quantitative imaging sequences into a standard clinical MRI protocol that allows absolute quantification to be performed with minimal impact upon the standard exam and its reporting.

**Methods.** Twenty patients due to undergo NAC for treatment of primary breast cancer were recruited to the study after providing written informed consent. Each underwent 2 MRI exams; baseline and following at least 2 cycles of NAC. MRI was performed at 1.5 T (Siemens Avanto) and included 3D fat-suppressed FLASH imaging of both breasts in the axial plane (TR/TE 4.1/1.2 ms, flip 10°, FOV 340 x 340 x 146 mm, matrix 384 x 384 x 104, acq. time 34 s). Imaging volumes were acquired before the injection of 0.1 mmol/kg Gd-DOTA and then at ~1.5, 2.1, 3.2, 4.3, 4.9, 5.5 & 6.0 mins after injection. Quantitative data were acquired over a similar 3D volume (340 x 340 x 150 mm, matrix 128 x 128 x 30) first using a series of segmented IR-trueFISP acquisitions (inter-segment TR 3 s, TR/TE 2.7/1.3 ms, flip 70°, acq. time 1 min) at TI 400, 680, 1200 & 2000 ms to measure baseline T1 and then a FLASH sequence (TR/TE 2.7/0.8 ms, flip 21°, acq. time 2 s) was used to acquire data during & following Gd-DOTA injection in bursts of 34, 16, 16 & 16 volumes acquired in an interleaved manner during the gaps between acquisition of the clinical data.

3D regions of interest were drawn in the descending aorta (to measure an arterial input function, AIF) and to encompass the enhancing tumor. SI-time data from these regions, combined with estimates of pre-contrast blood T1, tumor T1 and bolus arrival time (BAT), were analyzed using a 2 compartment exchange model (2CXM) [4] to derive estimates of tumor perfusion ( $F_b$ ), blood volume ( $v_b$ ), capillary permeability surface-area product (PS) and interstitial volume ( $v_e$ ).

**Results.** 18 baseline MRI studies were included (2 patients withdrew from the study); 2 of these 18 were not true baseline studies having been obtained after 1 cycle of NAC. 15 follow-up studies were successfully analyzed (2 technical failures were encountered and 1 tumor was too small to analyze following NAC). 11 patients were assessed by clinical imaging as responders at visit 2 while 7 showed minimal or no response. Analysis of the data obtained from the 16 untreated tumors at baseline revealed mean ( $\pm$ SD) parameter estimates: T1, 1075  $\pm$  75 ms;  $F_b$ , 57  $\pm$  29 ml/min/100 ml tissue;  $v_b$ , 22  $\pm$  14 ml/100 ml; PS, 9  $\pm$  6 ml/min/100 ml;  $v_e$ , 21  $\pm$  10 ml/100 ml. Following NAC there were significant changes in tumor perfusion but not in T1 or any other 2CXM parameter.  $F_b$  decreased in responders by 65  $\pm$  11% ( $n$  = 8) and in non-responders by 39  $\pm$  22% ( $n$  = 6).

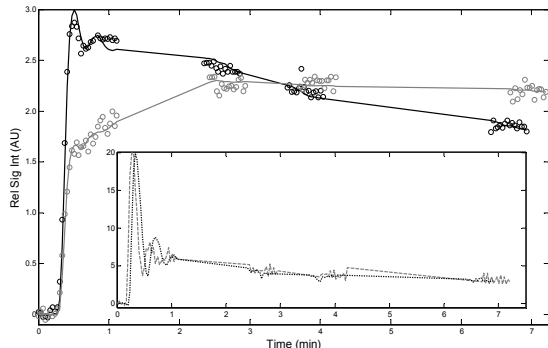


Fig. 1 Relative SI change against time in 1 tumor (+ AIFs) that responded to NAC. Pre-treatment (black,  $F_b$  = 80 ml/min/100 ml) and post 2 cycles of NAC (gray,  $F_b$  = 32 ml/min/100 ml).

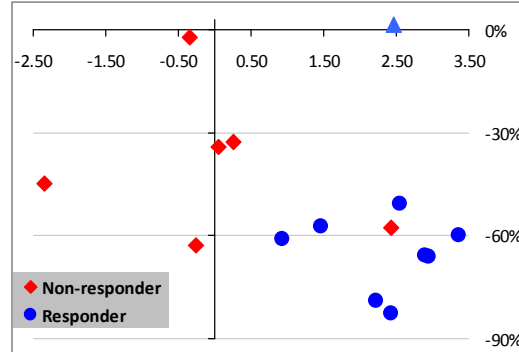


Fig. 2 % change in  $F_b$  (y-axis) plotted against change in BAT (s, x-axis) from baseline to follow-up MRI. PS (and  $K^{\text{trans}}$ ) in 1 tumor (triangle) changed substantially without a change in  $F_b$ .

**Discussion.** The quantitative protocol had minimal impact on clinical routine; all studies were reported in the normal way. The first and second pass of the contrast bolus through the descending aorta was captured by the initial burst of 34 rapid volume acquisitions (~70 s) and subsequent data for the AIF were linked by interpolation (see Fig. 1). These gaps in the DCE acquisition did not compromise model fitting; parameter estimates in the untreated tumors are very similar to figures reported previously [4,5], though MRI estimates of  $F_b$  in all 3 studies are higher than PET estimates [6].

A key aim of this preliminary study was to isolate the characteristics of microvascular function that change in response to NAC. It seems likely that a reduction in tumor perfusion, perhaps emphasized by delayed BAT (Fig. 2), rather than a change in PS is the main cause of the  $K^{\text{trans}}$  reduction seen in previous studies [1-3]. The combination of imaging protocol and data analysis shows promise and now requires testing in a larger patient cohort.

**Acknowledgments.** We are grateful to Trish Snowden and Jemma White for their hard work in establishing this study.

## References.

1. Delille et al, Radiology 2003;228:63;
2. Pickles et al, Breast Cancer Res Treat 2005;91:1;
3. Ah-See et al, Clin Cancer Res 2008;14:6580;
4. Brix et al, Magn Reson Med 2004;52:420;
5. Makkat et al, Radiology 2008;249:471;
6. Mankoff et al, J Nucl Med 2003;44:1806.