

Assessment of Apical Periodontitis by Size Comparison between MRI and CBCT

Elena Sophia Schreiber^{1,2}, Anna-Katinka Bracher¹, Erich Hell³, Johannes Ulrici³, Margrit-Ann Geibel², Leif-Konradin Sailer⁴, and Volker Rasche¹

¹Department of Internal Medicine II, University Hospital of Ulm, Ulm, BW, Germany, ²Department of Oral and Maxillofacial Surgery, University Hospital of Ulm, Ulm, BW, Germany, ³Sirona Dental Systems GmbH, Bensheim, Germany, ⁴DOC Praxisklinik im Wiley, Neu-Ulm, Germany

Background:

Bacterial inflammation causes apical periodontitis. Through an ignited root channel (pulpitis) or a deep gingival sulcus, bacteria can penetrate to the root point. Apical periodontitis can be classified into an acute type with pain symptomatology and a chronic type without pain. The current X-ray (XR) based imaging techniques (panoramic tomography (PT) and Cone Beam CT (CBCT)) are limited in delineating chronic and acute periapical lesions. Chronical apical periodontitis can be identified in the X-ray image by the related root resorption, hyperzementosis and osteitis. Acute lesions, however, are difficult to assess by x-ray before substantial bone degeneration. The applicability of MRI for the assessment of apical lesions has been shown before¹. The aim of this study was to clinically evaluate the applicability of MRI for the assessment of the apical periodontitis in direct comparison to CBCT.

	T1W spin echo	T2W spin echo
Echo time [ms]	7.2	60
Repetition time [ms]	625	2092
Pixel BW [Hz]	272	157
Acquired res. [mm ³]	0.5x0.5x1.5	0.5x0.5x1.5
Slices	10	10
TSE factor	8	11
Field of view [mm ³]	230x230x15	230x230x15
Scan time	9:06	5:43

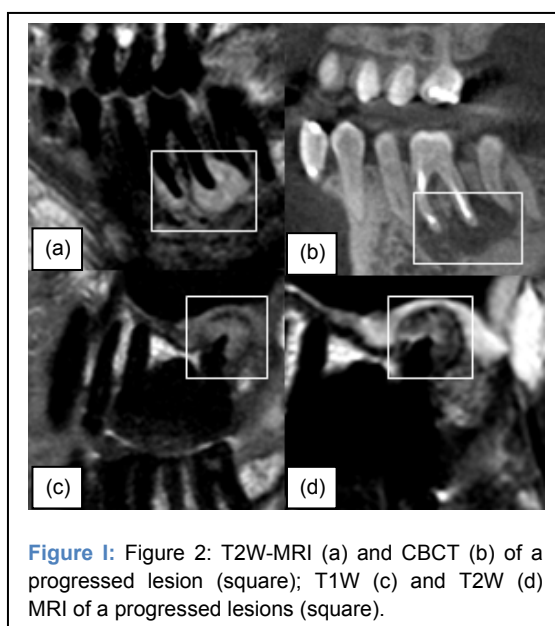
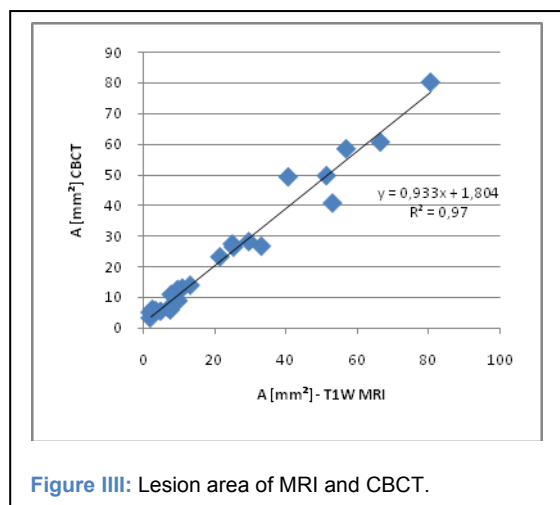
Table I: MRI Acquisition Protocol

Methods and Materials:

Thirty patients with 36 lesions in total were enrolled in this feasibility study. XR findings included minor to severe periapical lesions. All patients underwent a CBCT scan and an MRI investigation within 2 weeks. The CBCT data were obtained on a Galileos System (Sirona Dental Systems). All MRI data was acquired at a 3-Tesla whole body system (Achieva, Philips Medical, Best, Netherlands) with a 16-element neurovascular coil. The MRI imaging protocol comprised a high resolution multi-slice T1-weighted (T1W) acquisition for lesion identification and T2-weighted (T2W) multi-spin echo acquisition for lesion classification. Acquisition parameters are listed in Table I. MRI scans were planned in parasagittal orientation aligned with central line of the tooth of either side of the jaw. Location and size of the lesions were compared between T1W, T2W and CBCT. The CB CT data was reformatted in parasagittal direction similar to the MRI acquisition geometry. Lesion dimensions were quantified by their height *h*, width *w* and area *A* in all image modalities. Significance of differences were analyzed applying a two-tailed paired student's t-test.

Results:

All lesions identified in CBCT were clearly visible in T1W as well as in T2W MRI. The lesion size in T1W and T2W MRI corresponded well ($R^2=0.99$) with each other (p_{T1-T2} : $w>0.82$, $h>0.87$, $A>0.85$). However, compared with CBCT the lesion (T2W $R^2 = 0.81$, T1W $R^2 = 0.82$, $A R^2= 0.97$ (see fig.1)) dimension were slightly but significantly



larger in MRI (fig. 1 a,b, Table II) (p_{T1-DVT} : $w < 0.01$, $h < 0.01$, $A < 0.01$; p_{T2-DVT} : $w < 0.01$, $h < 0.01$, $A < 0.01$). Interestingly, 4 out of 5 clinically identified acute lesions showed a heterogeneous signal in T2W MRI. In the vicinity of the foramen a well circumscribed hyper-intense signal (fig 1 a (circle), d (arrow)) can be appreciated.

Discussion:

MRI can be applied for the identification of apical periodontitis with similar sensitivity as XR based techniques. The slight overestimation of the lesion dimension is likely caused by the higher sensitivity of MRI since substantial breakdown of the mineral structures is not required. The versatile contrast of MRI may facilitate the delineation of acute inflammation and cysts due to their higher signal intensity in T2w pictures. The clinical value and the accuracy of MRI in lesion classification needs to be proven in further clinical studies.

References: ¹Bracher AK et al.. ISMRM. 19; Montreal. Canada: 2011:2613