

Dental age estimation of living persons: comparison of MRI with the gold standard, the orthopantomogram

Pia Baumann^{1,2}, Thomas Widek¹, Heiko Merckens¹, Julian Boldt³, Andreas Petrovic^{1,4}, Barbara Kirnbauer⁵, Norbert Jakse⁵, and Eva Scheurer^{1,2}

¹Ludwig Boltzmann Institute for Clinical-Forensic Imaging, Graz, Austria, ²Medical University, Graz, Austria, ³Department of Prosthodontics, Julius Maximilians University, Würzburg, Germany, ⁴University of Technology, Institute of Medical Engineering, Graz, Austria, ⁵University Clinic for Oral and Maxillofacial Medicine, Graz, Austria

Introduction: In the last years the need for forensic age estimations in living adolescents increased with migration particularly from countries where birth dates are not reliably documented. Due to the strong resistance of the tooth development against illnesses and environmental conditions estimation of dental age is considered as an important part of the entire age estimation procedure. To date dental age estimation is performed on the basis of a panoramic X-ray (orthopantomogram, OPG) of the jaw where the stages of mineralization and eruption of the teeth, particularly of the third molars are evaluated [1, 2]. Based on published reference values for each stage, the evaluated stages are then converted to an age estimate in years. However, the use of ionizing radiation without medical indication is ethically controversial and not permitted in many countries. Thus, the aim of this study was to investigate if dental MRI can be used for the assessment of tooth development to yield qualitatively comparable results as the OPG.

Materials & Methods: 10 healthy volunteers (9 females, 1 male, age 20±2.6 years, range 14.5-22.5y) with at least two present third molars underwent an MRI scan of the jaw within 14 days after a clinically indicated OPG. The examinations were performed on a 3T Magnetom scanner (Tim Trio, Siemens AG, Erlangen, Germany) using an 8-channel receive-only multifunctional CPC coil (Noras MRI products GmbH, Hoechberg, Germany). The protocol consisted of a 3D TSE restore (TR/TE 172/10ms, resolution 0.6x0.6x1.0mm³) and a 3D constructive interference in steady state (CISS) (TR/TE 5.41/2.33ms, FA=30°, resolution 0.6x0.6x1.0mm³) sequence. Total acquisition time was 20:31 minutes. The coil was placed on both sides of the face covering the upper and the lower jaw with particular focus on the posterior parts. Both sequences were performed with two slabs which were angulated along the jaw. The OPGs and the MR images were independently read by a dentist with experience in dental staging and by a dentist without experience regarding age estimation. Mineralization and eruption stages of the molars were evaluated in both modalities according to the staging system established by Demirjian and Mincer [1, 2] with stages A-H for mineralization and stages A-D for eruption. Pooled data from both examiners were used to correlate the results of both, MRI and OPG, and linear regression with calculation of the Pearson's correlation coefficient was performed. For the assessment of inter-rater agreement Cohen's Kappa was calculated.

Results: A total of 118 molars were present in the examined subjects. After the exclusion of single teeth due to technical reasons (e.g., artifacts, superimposition) 112 molars were evaluated in the OPGs, and 110 molars in the MRI data. Only stages higher than C were seen for mineralization. As shown in Fig. 1 different stages were seen in good quality in both the OPG and the two MRI sequences. Fig. 2 demonstrates that the results of the OPG correlate linearly with the stages found in MRI. In mineralization (Fig. 2a) the stages E and F found in the OPG tended to be associated with stages up to 2 stages higher in MRI (linear regression: $y=0.7x+2.3$, $R=0.87$). In contrast, eruption (Fig. 2b) showed an almost perfect correlation between OPG and MRI ($y=0.99x+0.01$, $R=0.95$). Inter-rater agreement was moderate for mineralization (OPG: $\kappa=0.47$, MRI: $\kappa=0.53$), and good regarding eruption (OPG: $\kappa=0.72$, MRI: $\kappa=0.61$).

Discussion & Conclusion: The evaluation of dental development of molar teeth in MRI was compared to the current gold standard, i.e., the OPG. The same staging system could be used to assess mineralization and eruption. For eruption the correlation between OPG and MRI was excellent whereas the assessment of mineralization resulted in higher classifications in MR images. One reason might be that more stages for mineralization exist than for eruption resulting in smaller differences between two neighboring stages. Additionally, the evaluation of MRI data was difficult for the examiners due to various reasons associated with this unusual method in dentistry (e.g., 3D instead of projection data, different contrast behavior). The inter-rater agreement was better for eruption than for mineralization and almost equal for MRI and the OPG. However, the differences between the two examiners concerning their experience in dental age estimation seem to be the main reason for the limited agreement.

The comparison of dental MRI with the OPG demonstrates that there is a relatively good correlation between both imaging methods. However, further investigations need to be performed, i.e., a correlation of the results of the MRI with known chronological age and the examination of larger cohort including also younger subjects. Additionally, it was shown that the training and the experience of the examiners concerning the evaluation of dental development as well as the reading of MRI data has an important influence on the outcome. The results of this study could be the first step towards a replacement of the OPG associated with ionizing radiation by MRI.

References: [1] Demirjian et al, Hum Biol 1973, 45(2):211-27; [2] Mincer et al, J Forensic Sci 1993, 38(2):379-90

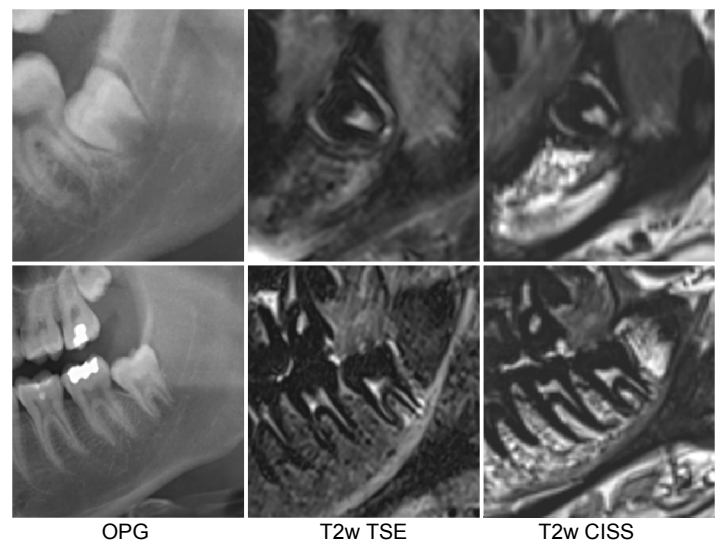


Fig. 1 Example of two different stages of the third molar upper row: female, age 18.5y, mineralization stage E, eruption stage B lower row: male, age 18.6y, mineralization stage G, eruption stage C.

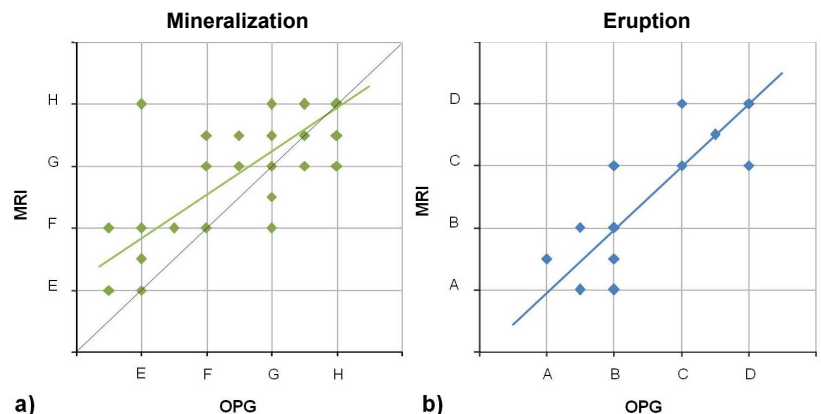


Fig. 2 Correlation of the evaluated dental stages for a) mineralization (grey line shows unity) and b) eruption in OPG and MRI data, respectively, with corresponding linear regression functions.