

# Visualization of Renal Artery and Its Branches of the Middle-aged Healthy Adults: The Initial Study of Non-Contrast-Enhanced MR Angiography Using a Time-Spatial Labeling Inversion Pulse

Mengyu Liu<sup>1</sup>, Huadan Xue<sup>2</sup>, Xuan Wang<sup>2</sup>, Yuan Liu<sup>2</sup>, and Zhengyu Jin<sup>2</sup>

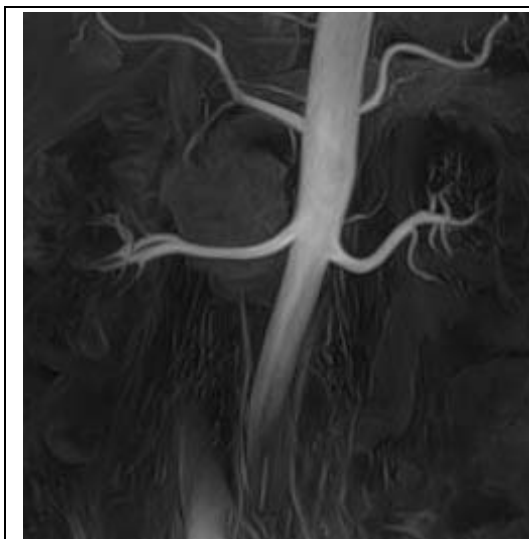
<sup>1</sup>PLA general hospital, Beijing, Beijing, China, People's Republic of, <sup>2</sup>Peking Union Medical College Hospital

**Purpose:** To evaluate visibility of renal artery and its branches using three-dimensional (3D) non-contrast enhanced MR angiography with a time-spatial labeling inversion pulse (Time-SLIP) in middle-aged subjects, and to provide an optimal value of the black blood inversion time (BBTI).

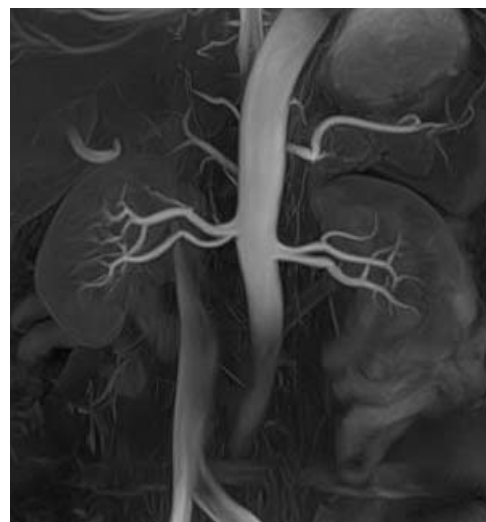
**Materials and Methods:** Institutional review board approval and written informed consent were obtained for each volunteers. 3D non-contrast enhanced MR angiography images with a Time-SLIP were obtained in 26 middle-aged healthy volunteers (M:F=15:11; mean age 52.8±1.9yrs) with a 1.5T clinical system (Vantage XGV Power By Atlas, Toshiba, Japan). Three coronal sequences with different BBTI (900, 1200, 1500 ms) were performed for each volunteer, referred to as sequence A, B, C, respectively. Relative signal intensity (rSI) of renal artery, visibility score (Rank 1-4) in 3 segments (1 indicated origin to first renal arterial branch; 2, from first renal arterial branch to renal parenchyma; 3, within parenchyma) of the renal artery and the numbers of the branches were evaluated as indexes of the Time-SLIP sequence image quality.

**Results:** All subjects received all sequences successfully. The mean rSI value were 5.06±3.65, 1.79±0.59, 1.13±0.42 for sequence A, B, C, respectively. The mean visibility score of the first segment were 3.85±0.46, 3.96±0.20, 3.81±0.40; the second segment were 3.54±0.81, 3.50±0.58, 3.23±0.65 and the third segment were 2.08±0.63, 2.35±0.49, 2.00±0.49, respectively. The mean numbers of the branches were 2.88±0.91, 3.38±0.70, 3.35±1.02, respectively. Among them, sequence A yielded significantly higher relatively signal intensity than the other two sequences; sequence B had better visibility scores of the three segments of the renal artery and the numbers of branches. There were 53.8% of artery variants including accessory renal artery, early branching artery and multi renal arteries in unilateral or bilateral kidney.

**Conclusion:** Balanced SSFP non-contrast-enhanced MR angiography showed excellent visualization of the renal artery system. An coronal sequence with BBTI=1200ms was considered to be the optimal choice for this purpose in middle-aged healthy subjects.



**Fig 1** visualization of renal artery with BBTI of 1200ms in a 54 female subject. Bilateral renal artery anatomy showed clearly.



**Fig 2** visualization of renal artery with BBTI of 1200ms in a 52 male subject. Bilateral renal artery showed early branching.