

# Prediction of histopathologic grade of hepatocellular carcinoma using current MRI sequences

Chansik An<sup>1</sup>, Mi-Suk Park<sup>1</sup>, Myeong-Jin Kim<sup>1</sup>, Yeo-Eun Kim<sup>1</sup>, Woo-Suk Chung<sup>1</sup>, Hyae Min Jeon<sup>2</sup>, and Ki-Whang Kim<sup>1</sup>

<sup>1</sup>Diagnostic radiology, Yonsei University Health System, Seoul, Korea, Republic of, <sup>2</sup>Pathology, Yonsei University Health System, Seoul, Korea, Republic of

**Introduction:** Predicting the grade of hepatocellular carcinoma (HCC) preoperatively is important, because the histopathologic differentiation of HCC is known to be an important prognostic factor in terms of survival as well as tumor recurrence. Recent advances in magnetic resonance (MR) imaging have led to the clinical application of state-of-the-art MR sequences to liver imaging. The aim of our study is to investigate the effectiveness of current MR sequences in estimating histopathologic grade of HCC; diffusion-weighted images (DWI), dynamic subtraction of precontrast from arterial phase images, and hepatobiliary phase (HBP) images.

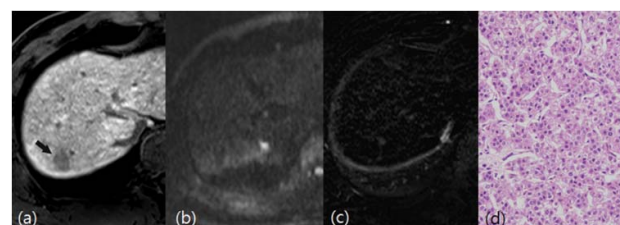
**Methods:** This retrospective study was approved by the institutional review board; informed consent was waived. Gd-EOB-DTPA-enhanced MRIs with DWI of 201 surgically resected HCCs in 175 patients were independently reviewed by two abdominal radiologists. MRI was performed with a 3.0-T MR system (MAGNETOM Trio a Tim; Syngo MR B15; Siemens Medical Solutions, Erlangen, Germany) and subtraction of multi-phasic contrast enhanced dynamic series was automatically acquired. The reviewers evaluated the signal intensity of each tumor on DWI (hyperintense or iso-hypointense on high b-value DWI (b=800)), on subtraction images of precontrast from arterial phase images (hyperintense or iso-hypointense), and on HBP images (hypointense or iso-hyperintense). The incidence of signal intensity and the relationship between signal intensity and histopathologic grade were assessed for each sequence and a combination of sequences. The statistical differences were assessed using the generalized linear mixed model in order to control the effects of clustered data.

**Results:** Pathologic examinations revealed 37 well-, 130 moderately, and 34 poorly differentiated HCCs. On DWI, 74.2% (23/31) of HCCs without restricted diffusion and 8.2% (14/170) of HCCs with restricted diffusion were well-differentiated ( $p < .001$ ). On subtraction imaging, 81.3% (13/16) of HCCs without arterial enhancement and 13% (24/185) with arterial enhancement were well differentiated ( $p < .001$ ). On HBP images, no significant difference was seen in signal intensity among different grades ( $p = .33$ ). When lesions were divided into three groups based on combined findings on DWI and subtraction imaging (Group 1: no positive findings (**Figure 1**); Group 2: only one positive findings; Group 3: two positive findings, with positive findings being restricted diffusion and arterial enhancement), a linear trend was observed between group and grade ( $p < .001$ ) (**Table 1**). The positive predictive value (PPV) of Group 1 in predicting well- differentiated HCC was 100%, higher than the PPV of individual positive findings on DWI (74%) or subtraction imaging (81%) (**Table 2**).

**Conclusions:** DWI and subtraction imaging are helpful for predicting the HCC histopathologic grade. The combination of no restricted diffusion and no arterial enhancement has a high PPV for distinguishing well-differentiated from higher grade HCCs.

## References

1. Oishi K, Itamoto T, Amano H et al (2007) Clinicopathologic features of poorly differentiated hepatocellular carcinoma. J Surg Oncol 95:311-316
2. Nishie A, Tajima T, Asayama Y et al (2010) Diagnostic performance of apparent diffusion coefficient for predicting histological grade of hepatocellular carcinoma. Eur J Radiol 80:e29-e33
3. Nasu K, Kuroki Y, Tsukamoto T, Nakajima H, Mori K, Minami M (2009) Diffusion-weighted imaging of surgically resected hepatocellular carcinoma: imaging characteristics and relationship among signal intensity, apparent diffusion coefficient, and histopathologic grade. AJR, American journal of roentgenology 193:438-444



**Figure 1** HCC lesion belonging to Group 1 (no positive finding on DWI and subtraction imaging) in 58-year-old man. (a) Transverse hepatobiliary phase MR image shows a 1.7 cm discrete nodule in liver segment VII. (b) High b-value DWI and (c) subtraction of precontrast from arterial phase images show no definite visible lesion at this level. (d) Histologic slice reveals well-differentiated HCC (Hematoxylin-eosin stain; original magnification, x200).

Table 1: Relationship Between Combined Signal Intensities on DWI/Subtraction Imaging and HCC grade				
Signal Intensities on DWI/Subtraction	No (%) of HCC lesions			Total
	Well-differentiated	Moderately differentiated	Poorly differentiated	
No positive finding* (Group 1)	13 (100)	0 (0)	0 (0)	13 (100)
One positive finding (Group2)	10 (48)	10 (48)	1 (4)	21 (100)
Two positive findings (Group3)	14 (8)	120 (72)	33 (20)	167 (100)

**Note.** – The grade tends to rise as the lesion belongs to the higher group. This linear trend was revealed to be statistically significant by the generalized linear mixed model ( $p < .01$ ).

\* Positive findings mean restricted diffusion on DWI or arterial enhancement on subtraction imaging.

Table 2: Sensitivity, Specificity, and PPV in Differentiating Well-differentiated HCCs			
	Sensitivity (95% CI)	Specificity (95% CI)	PPV (95% CI)
No positive finding* on DWI	0.62 (0.46, 0.76)	0.95 (0.9, 0.97)	0.74 (0.57, 0.86)
No positive finding on Subtraction	0.35 (0.32, 0.51)	0.98 (0.94, 0.99)	0.81 (0.57, 0.93)
No positive findings on DWI and Subtraction (Group 1)	0.35 (0.20, 0.53)	1.00 (0.98, 1.00)	1.00 (NA)

**Note.** – CI = confidence interval, PPV = positive predictive value, NA = not assessable

\* Positive findings mean restricted diffusion on DWI or arterial enhancement on subtraction imaging.