

# Comparison of small bowel aperistalsis using glucagon versus hyoscine administered intravenously or intramuscularly

Johannes M Froehlich<sup>1,2</sup>, Nicole Graf<sup>3</sup>, Constantin von Weymarn<sup>1</sup>, Christoph A Binkert<sup>1</sup>, Klaus Hergan<sup>4</sup>, and Andreas Gutzzeit<sup>1,4</sup>

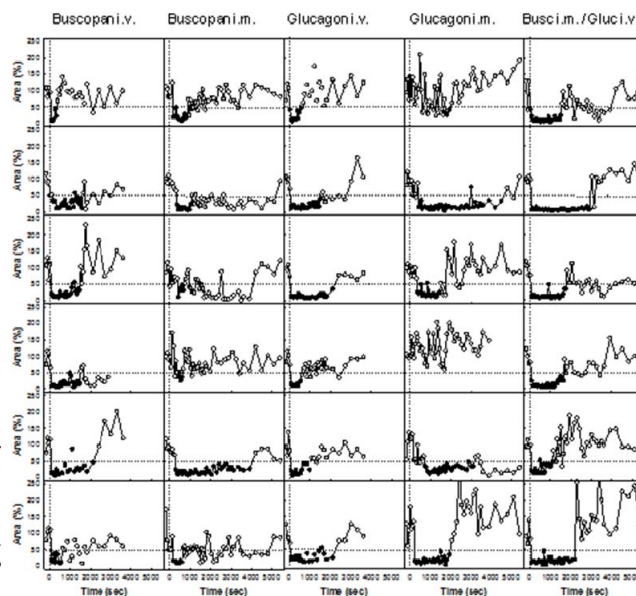
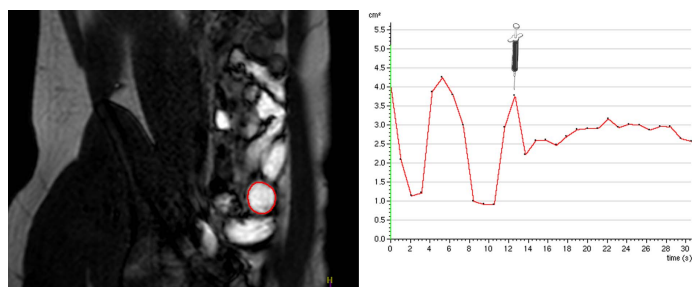
<sup>1</sup>Department of Radiology, Cantonal Hospital, Winterthur, Switzerland, <sup>2</sup>Scientific Affairs, Guerbet, Zurich, Switzerland, <sup>3</sup>Clinical Trials Center, Center for Clinical Research, University Hospital, Zurich, Switzerland, <sup>4</sup>Department of Radiology, Paracelsus Medical University, Salzburg, Austria

**Introduction:** Small bowel motility may consistently deteriorate abdominal or pelvic image quality and cause movement artifacts when using modalities which are sensitive to motion such as MRI and angiography. Therefore, spasmolytic agents are routinely used in the clinical setting such as glucagon (GLU; GlucaGen®) or hyoscine N-butylbromide (HBB; Buscopan®) [1,2]. GLU is a protein consisting of several amino acids, and has paralytic effects on the smooth muscles of the gastrointestinal tract via activation of glucagon-like protein -2 receptors (GLP-2). HBB exerts an anticholinergic effect over muscarinic receptors located on visceral smooth muscles. GLU as well as HBB can be administered by the intravenous or intramuscular route. However, little is known about the efficacy of these two agents when administered via different routes. Knowledge about the commencement, efficacy and termination of aperistaltic effects is essential for planning and performing imaging procedures in the abdomen and pelvis. The aim of our study was to evaluate the aperistaltic effect of Glucagon and Hyoscine using different routes of administration (i.v., i.m.), and their combination, in order to establish the optimal regimen for spasmolysis.

**Materials and Methods:** After obtaining institutional review board approval and the volunteers' informed written consent, a prospective clinical study was performed with acquisition of MRI data from March 2010 to February 2011. Six volunteers (one woman, five men; age range 26 to 52 years, mean age 30 years) without any contraindications, abdominal disease or previous operations were included in the study. To ensure standardized small bowel distension, all volunteers ingested over 60 min a preparation consisting of 1600 mL of water combined with 20 mL gadoterate (0.5 Mol/L; Dotarem®) and 23.2 g Metamucil mite (psyllium husk, maltodextrin) prior to each MR examination. The volunteers underwent the MR examinations with five different pharmacological regimens (40mg hyoscine N-butylbromide; Buscopan® i.v. and i.m., 1mg Glucagon i.v. and i.m., 1mg Glucagon i.v. plus 40mg hyoscine i.m.) in random order, within a maximum time period of two months and with at least a one-week delay between individual measurements. The 1.5T MR protocol consisted of a scout, a reference scan and a coronal 3D T1-w overview of the entire abdomen. Well visible small bowel loops were imaged dynamically during breathholds using a sagittal 2D T1-w gradient echo pulse sequence (Fig. 1). With the help of a cardiac analysis software cross-section areas were measured and plotted over time (Fig. 1). For each breathhold covering app. 30 sec the standard-deviation of the cross-section areas were determined. Aperistalsis was defined as a reduction of variability for single breathholds beyond 50%. The baseline of 100% was pre-defined at the beginning before administration of drugs as a mean of three measurements. A 50% decrease of variability helps to determine onset of effect, duration of aperistalsis and drug's efficacy (Fig. 2).

**Fig. 1** (beyond): Sagittal view of the T1-w MRI of the bowel loop of interest framed by the use of semiautomatic software and followed over time. The plot on the right shows the change in area of the bowel lumen in mm<sup>2</sup> over time. The bowel reveals rhythmic motion under normal conditions. Spasmolysis with complete arrest of motility occurs shortly after i.v. GLU (syringe).

**Fig 2** (graph on the right side): Overview of all six volunteers (lines) with their respective drug administration modes (rows) covering the entire MRI measurement (=60 min for i.v. administrations / 90 min for i.m. or combined schemes). The black bold dots represent the phase where spasmolysis is rated as sufficient corresponding to a standard deviation of amplitudes beyond 50% compared to mean baseline movement equal to 100%.



**Results:** Both HBB i.v. and GLU i.v. arrested bowel movement early, i.e., 85 ( $\pm 24.5$ ) and 65 ( $\pm 24.5$ ) sec after drug administration, respectively. Aperistalsis lasted for 21 min ( $\pm 12.3$ ) in case of i.v. HBB compared to 23.1 min ( $\pm 14$ ) after GLU. I.m. administration was effective after a significantly longer ( $p=0.001$ ; Wilcoxon signed ranks test) delay of 310 ( $\pm 110.1$ ) sec for HBB and 696 ( $\pm 609.8$ ) sec for GLU. I.m. administration revealed greater inter-individual differences ( $p=0.012$ ; Brown-Forsythe test). Nonetheless, compared to the other drug administrations, the combined scheme provides not only an early onset of effect (65 sec), but also the longest period of aperistalsis (31 $\pm$ 10.7 min) and the most reduced motion in relation to the baseline measurement. Thus this scheme provides also a high predictability of effect. The individual plots for all volunteers and drugs show that the effect varies interindividually with a certain common paradigm related to the mode of administration (Fig 2).

**Discussion and Conclusion:** These preliminary results achieved in volunteers confirm earlier clinical results that i.v. administration provides immediate spasmolysis [3] while the effect is more delayed in case of i.m. administration. Moreover, i.m. mode had a less reliable effect over time with larger interindividual variation for effect of onset and duration. As the drug substances are released slower into the systemic circulation, they might not exceed the concentration necessary for inhibiting peristalsis. Thus, clinical use of a single agent administered via the i.m. route, although widely practiced, may be suboptimal because of the unpredictability in the onset and duration of effects. The combined use of i.v. GLU and i.m. HBB provides an immediate effect, lasting the longest period of time and with the highest efficacy. Besides the optimized pharmacokinetics this scheme profits probably also of activation of two different receptor systems both leading to aperistalsis. Overall, the combined scheme provides the highest degree of predictability for spasmolysis.

## References:

1. Dubé PE, Brubaker PL (2007) Frontiers in glucagon-like peptide-2: multiple actions, multiple mediators. *Am J Physiol Endocrinol Metab* 293: E460-E465
2. Tytgat GN (2008) Hyoscine butylbromide - a review on its parenteral use in acute abdominal spasm and as an aid in abdominal diagnostic and therapeutic procedures. *Curr Med Res Opin* 24: 3159-3173
3. Froehlich JM, Daenzer M, von Weymarn C et al. (2009) Aperistaltic effect of hyoscine N-butylbromide versus glucagon on the small bowel assessed by magnetic resonance imaging. *Eur Radiol* 19: 1387-1393