

In Vivo Evaluation of a Novel Left Ventricular Mechanical Assist Device Using Cardiac MRI

Jeremy R McGarvey^{1,2}, Kevin J Koomalsingh^{1,2}, Norihiro Kondo², Manabu Takebe², Walter R.T. Witschey^{2,3}, Gerald A. Zsido², Christen M. Dillard², Kristina Lau², Gabrielle Pilla², Joseph H. Gorman^{1,2}, Robert C. Gorman^{1,2}, and James J. Pilla^{2,3}

¹Department of Surgery, University of Pennsylvania Health System, Philadelphia, PA, United States, ²Gorman Cardiovascular Research Lab, Harrison Department of Surgical Research, Glenolden, PA, United States, ³Department of Radiology, University of Pennsylvania Health System, Philadelphia, PA, United States

Objectives: Adverse ventricular remodeling after myocardial infarction remains a difficult clinical challenge¹. While many treatment modalities have been described for ischemic heart failure, their efficacy remains unsatisfactory or controversial². We have developed a novel MRI-compatible epicardial left ventricular (LV) assist device that can actively contract infarcted myocardium in synchrony with the functional remote region. Cardiac MRI was utilized to better understand the functional and geometric changes of the heart following placement of this device in a porcine heart failure model.

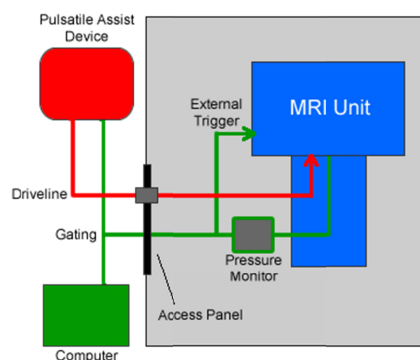


Figure 1: Equipment Schematic

Methods: Three Yorkshire swine underwent direct ligation of the circumflex artery via thoracotomy to create a posterolateral myocardial infarction (MI). Twelve weeks post-infarct, a custom-made inflatable neoprene bladder was placed on the transmurally infarcted epicardial surface. LV pressures were continuously recorded using a Millar pressure transducer catheter (Millar Instruments, Houston, TX). A pressure-gated, synchronous pulsation device was connected to the epicardial bladder and positioned outside the magnetic field. The bladder was then inflated during systole and deflated during diastole via rapidly exchanged helium gas. Using a 3.0T Siemens MAGNETOM Trio A Tim, the animals then underwent cardiac and respiratory gated cardiac MRI (Figure 1). LV volumes with the device off (deflated) and during active assistance were obtained using a 2D SPGR sequence with the following parameters: TR/TE/FA=24.2ms/2.4ms/15°, BW=400, FOV=300mm x 243mm, Matrix=192x156, slice thickness=4mm, Ave.=2, cardiac phases=16-20 depending on heart rate. LV volumes and ejection fraction (EF) were then calculated using ImageJ image analysis software. LV function was compared using a paired t-test.

Results: We successfully implanted and safely imaged the epicardial active assist device in all three animals. While being assisted, MRI showed a clear concave deformity over the infarct area during systole, while diastolic geometry was largely preserved (Figure 1a&b). When compared with non-assist, synchronized epicardial assistance on the infarct area improved EF dramatically ($34.1 \pm 7.8\%$ vs. $22.8 \pm 9.2\%$, $p=0.02$). Similarly, end systolic volume was significantly decreased in the assisted group ($75.7 \pm 25.7\text{ml}$ vs. $90.3\text{ml} \pm 28.8$, $p=0.01$). Stroke volume also increased in the assisted group and showed a trend towards significance ($37.4 \pm 4.4\text{ml}$ vs. $25.0 \pm 6.7\text{ml}$, $p=0.08$). End diastolic volume did not change between treatments ($113 \pm 24.8\text{ml}$ vs. $115.4 \pm 22.1\text{ml}$, $p=0.5$).

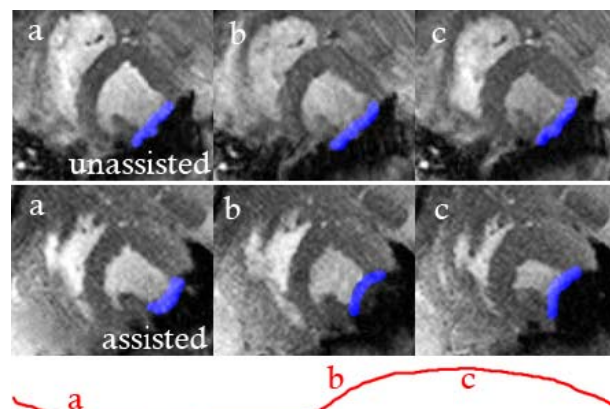
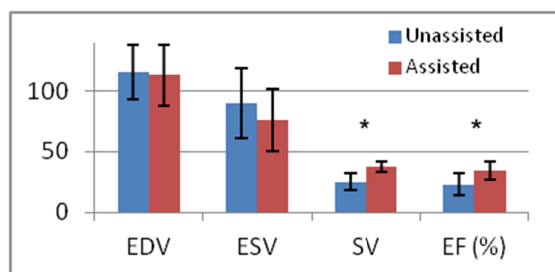


Figure 2: Short axis MRI cine images during unassisted (top) and assisted (bottom) systole relative to LV pressure (red line). Superimposed blue area overlies infarcted myocardium.



Conclusions: Cardiac MRI was successfully used to assess LV function and geometry after placement of a novel epicardial assist device. Utilizing a SPGR cine sequence, the assist device was found to increase stroke volume and EF in a chronic posterolateral infarct model. Additionally, the rapidly inflated bladder creates a significant concavity over the infarct area during systole, thereby displacing blood volume from adynamic myocardium to functional remote myocardium. As such, we have described for the first time *in vivo* cardiac MRI evaluation of ventricular function after placement of a non-ferromagnetic mechanical assist device.

Acknowledgements: This research was supported by NIH R01-HL63954.

References: 1) Bui, A. L. *et al.* Epidemiology and Risk Profile of Heart Failure. *Nat. Rev. Cardiol.* 8, 30–41 (2011)
2) George, T. J. *et al.* Surgical Treatment of Advanced Heart Failure: Alternatives to Heart Transplantation and Mechanical Circulatory Assist Devices. *Prog Cardiovasc Dis.* 54, 115-131 (2011)