

Monitoring amyloid deposition and therapeutic clearance using equilibrium contrast MRI

Adrienne E Campbell^{1,2}, Anthony N Price³, Stephan Ellmerich⁴, Paul Simons⁴, Raya Al-Shawi⁴, Rupinder Ghatrora⁵, Tammy L Kalber⁵, Philip N Hawkins⁴, Roger J Ordidge⁶, James C Moon⁷, Mark B Pepys⁴, and Mark F Lythgoe⁵

¹Centre for Advanced Biomedical Imaging, Division of Medicine and Institute of Child Health, University College London, London, London, United Kingdom, ²Department of Medical Physics and Bioengineering, University College London, London, United Kingdom, ³Robert Steiner MRI Unit, Imaging Sciences Department, Hammersmith Hospital, Imperial College London, London, United Kingdom, ⁴Wolfson Drug Discovery Unit, Centre for Amyloidosis and Acute Phase Proteins, Division of Medicine, University College London, London, United Kingdom, ⁵Centre for Advanced Biomedical Imaging, Division of Medicine and Institute of Child Health, University College London, London, United Kingdom, ⁶Centre for Neuroscience, University of Melbourne, Melbourne, Australia, ⁷Heart Hospital and Division of Medicine, University College London, London, United Kingdom

INTRODUCTION: Systemic amyloidosis, in which amyloid fibrils are deposited extracellularly in the viscera and connective tissues, damages the structure and function of tissues, and cardiac involvement is often a major cause of morbidity and mortality [1]. New therapies to directly promote removal of amyloid deposits are being developed [2] and there is an urgent need for readily available, non-invasive, methods for detecting and quantifying amyloid *in vivo*. Equilibrium contrast MRI (EQ-MRI) [3,4] is a technique used to estimate the distribution volume of gadolinium ($V_{d,Gd}$), an index of extracellular space expansion. EQ-MRI exploits the extracellular deposition of Gd and the direct relationship between T_1 and Gd concentration for the calculation of $V_{d,Gd}$.

Here we report the *in vivo* monitoring of amyloidosis by EQ-MRI in a new transgenic mouse model of systemic amyloid A protein (AA) amyloidosis [5]. Initially, global cardiac function was calculated from cine imaging and amyloid deposits were sought by EQ-MRI in the heart and liver. Furthermore, the effects of a novel therapy which eliminates visceral amyloid deposits were serially monitored in the liver and spleen.

METHODS: Imaging was performed on an Agilent 9.4T scanner (Agilent Technologies, Santa Clara, USA) with 35mm or 39 mm RF coil (RAPID Biomed, Rimpar, Germany). An inducible transgenic model of murine AA amyloidosis, in which mouse serum amyloid A protein expression is controlled by oral administration of doxycycline, was studied [5]. For initial assessment of MR markers, cine imaging was used to calculate global cardiac function and EQ-MRI was used to calculate $V_{d,Gd}$ in the heart and liver of 11 amyloidotic animals and 10 control animals. Comparisons of $V_{d,Gd}$ between groups were performed using rank-sum statistical tests and $V_{d,Gd}$ was correlated with histological amyloid load using Spearman's rho (ρ) correlation coefficient. Amyloid load was assessed using Congo red stain under cross-polarized light, and given a score of 0-5 by an experienced observer. Four mice were also monitored by EQ-MRI, applied in the liver and spleen, during the induction of amyloidosis and its regression induced by treatment with human serum amyloid P component (SAP) followed by anti-human SAP antibody in single doses[2]. $V_{d,Gd}$ values were normalized to the baseline data point for comparisons and the trend during therapy was assessed using a linear regression.

Cine MRI: Global cardiac function was calculated from double gated spoiled gradient echo cine images (TE/TR = 1.2/4.5-5ms, cine frames= 20, in-plane resolution=200 μ m, slice thickness = 1mm, 10 short-axis slices) using the freely available software Segment (<http://segment.heiberg.se/>).

EQ-MRI: Gd concentration equilibrium was generated in blood and tissue by a primed infusion: a bolus of 0.6mmol/kg followed at 10 min by 0.005mmol/kg/min infusion of Magnevist (Schering, Berlin). An ECG-gated Look-Locker technique [6] (TE/TR(inv)/TR(RF)=1.18ms/13.5s/RR-interval, flip=8°, in-plane resolution=200 μ m, slice thickness=1.5mm) was used to measure the T_1 pre- and post-contrast (15 min, in equilibrium) with a 3-parameter fit for ROIs in the left ventricle blood pool and tissue. $V_{d,Gd}$ was then calculated using:
$$V_d = (1 - Hct) \frac{\Delta R_{1,tissue}}{\Delta R_{1,blood}}$$

where $R_1 = 1/T_1$ and Hct is the group mean hematocrit, measured from tail-vein blood samples.

RESULTS: This model of amyloidosis develops modest cardiac amyloid deposits as well as extensive liver and spleen amyloid deposits. Cardiac function was not impaired in amyloidotic animals ($p = 0.35$, on average). However, $V_{d,Gd}$ was increased in the heart ($p < 0.005$) and the liver ($p < 0.0005$). In addition, there was a strong positive correlation between $V_{d,Gd}$ and amyloid load (Fig. 1, Myocardium: $\rho = 0.67$, $p < 0.01$; Liver: $\rho = 0.87$, $p < 0.01$). $V_{d,Gd}$ increased in the liver and spleen during the induction of amyloidosis and steadily returned to baseline after therapy (Fig. 2) with a significant trend (liver and spleen: $p < 0.01$) confirmed by linear regression.

Figure 1 $V_{d,Gd}$ plotted against histological amyloid score in a) the myocardium and b) the liver. A positive trend between amyloid score and $V_{d,Gd}$ was observed.

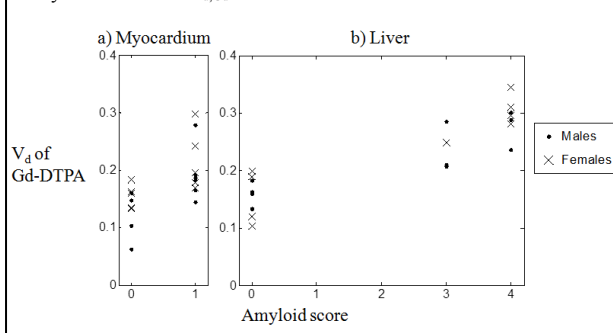
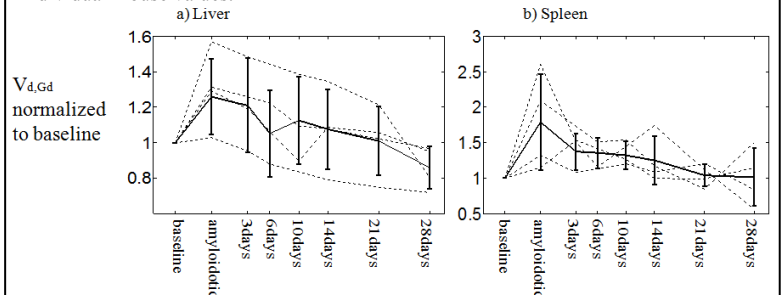


Figure 2 $V_{d,Gd}$ plotted for a) the liver and b) the spleen in transgenic mice before induction of amyloidosis (baseline), after induction but before treatment (amyloidotic) and at intervals following treatment, each normalized to the baseline value. The solid line shows the mean (\pm standard deviation) of the group; the dotted lines show the individual mouse values.



DISCUSSION: Modest amyloid deposits in the heart were clearly detected by EQ-MRI, even when cardiac function was not measurably impaired. There was also excellent discrimination in the liver values between control and amyloidotic mice. After treatment with anti-human SAP antibody, which causes the elimination of splenic and hepatic amyloid deposits [2], $V_{d,Gd}$ returned to normal in the liver and spleen suggesting that EQ-MRI is a promising approach for monitoring therapeutically induced amyloid regression. Importantly, no process other than amyloid deposition and regression is involved in this model of amyloidosis and the present results therefore support our interpretation of $V_{d,Gd}$ as an index of extracellular space volume. Trends in $V_{d,Gd}$ were apparent in the individual mice demonstrating that the method could be used for monitoring therapy in patients. Clinical measurement of $V_{d,Gd}$ is straightforward and is applicable to multiple organs within one scanning session. In addition, pixel-wise volume maps could be used to assess local variations in $V_{d,Gd}$ during amyloid deposition and regression.

In conclusion, EQ-MRI measurement of the volume of distribution of gadolinium is a sensitive marker of amyloid deposits with potential application for early detection of amyloidosis and for monitoring therapies which promote clearance of amyloid deposits.

REFERENCES: [1] Pepys MB. *Annu Rev Med* 2006, **57**:223-41. [2] Bodin K et al. *Nature* 2010, **268**: 93-97. [3] Flett AS et al. *Circulation* 2010, **122**: 138-44. [4] Campbell A et al. *ISMRM* 19(2011): 1354. [5] Simons P et al. *Amyloid* April 2010, **17**(suppl): 45-46. [6] Kober F et al. *MRM* 2004, **51**:62-67.