

CONTRAST-ENHANCED MAGNETIC RESONANCE ANGIOGRAPHY IN MANAGEMENT OF PULMONARY ARTERIO-VEINUS MALFORMATIONS IN PATIENTS WITH HHT (OSLER DISEASE)

Guenther Schneider¹, Arno Buecker¹, Alexander Massmann¹, and Peter Fries¹
¹Diagnostic and Interventional Radiology, Saarland University Hospital, Homburg, Germany

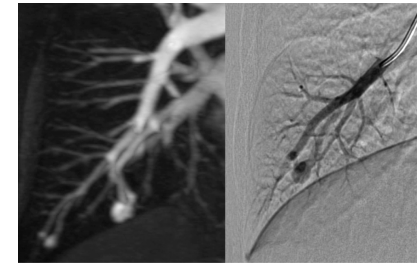
Purpose: To evaluate contrast-enhanced magnetic resonance angiography (CE-MRA) for management of pulmonary arterio-venous malformations (PAVM) in patients with hereditary hemorrhagic telangiectasia (HHT). CE-MRA as well was used as a screening procedure for the detection of pulmonary AVMs as it was used for follow-up of patients after catheter-based embolization-therapy for detection of reperfused PAVMs.

Material and Methods: Between 1999 and 2011 a total of 286 patients (mean age 45.9y, male 118, female 168) with confirmed HHT or first degree relatives underwent screening pulmonary CE-MRA (Gadolinium-BOPTA (MultiHance) 0.1 mmol/kg bodyweight) for detection of PAVMs. CE-MRA was performed on 1.5 Tesla units, since 2010 a Siemens Magnetom Aera was used for imaging. Since 2010 time-resolved imaging using the TWIST technique after injection of 2 ml MultiHance was used for bolus timing of a high resolution CE-MRA of pulmonary vasculature. This time-resolved imaging in addition allows for estimation of flow dynamics in PAVMs. Before 2010 a standard bolus timing sequence was used for timing of high resolution CE 3D GRE-Sequences. In addition to pulmonary

PAVM diameter	No. of PAVMs
< 5 mm	83
5 - 10 mm	117
11 - 15 mm	39
16 - 20 mm	34
21 - 25 mm	24
26 - 30 mm	17
> 30 mm	9

Comparison between CE-MRA and global DSA in detection of PAVMs			
Patients n = 74	CE-MRA	global DSA	
No. of PAVMs	263	205 [77.9%]	p < 0.001

screening all patients underwent unenhanced screening of the brain and the liver for possible involvement of these organs in HHT. Patients with at least one PAVM > 5 mm or a feeding pulmonary artery diameter >3 mm were referred for catheter angiography (DSA) for embolization-therapy. Following embolization therapy, patients underwent



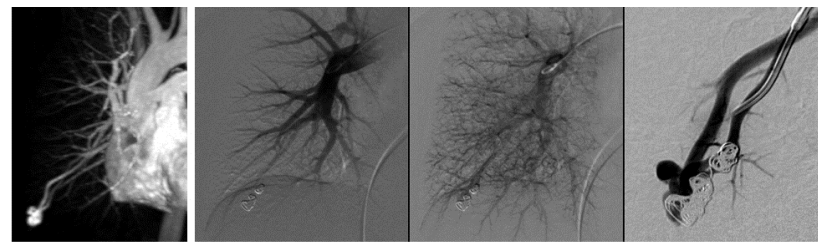
CE-MRA global DSA

follow-up CE-MRA for detection of reperfused respectively newly developed PAVMs 3 month, 12 month and thereafter in case of no reperfusion in 2-year intervals.

Results: Overall, CE-MRA detected 323 PAVM in 97 of 286 patients (34%). 149 PAVMs in 44 men, 174 PAVMs in 53 women, of which 89 PAVMs were found in 32 women of childbearing age. Most PAVMs detected on CE-MRA were small (<10 mm). 74 of 97 patients with 263 PAVMs detected on CE-MRA underwent catheter angiography for embolization therapy of PAVMs. Significantly (p<0.001) fewer PAVMs (205/263 [78%]) were demonstrated on global DSA, the remaining PAVMs could only be demonstrated after selective

Newly developed PAVMs on follow-up CE-MRA		
	reperfused PAVM	new PAVM
PAVM	32	57
No. of Patients	24	14
Interval	3 months - 7yrs	1 - 7yrs

catheterization of the feeding arteries. A total of 191 PAVMs were embolized in 74 patients using platinum coils. CE-MRA was rated as very useful by radiologists performing the interventional procedures using subvolume MIP-projections as a roadmap to selectively catheterize the feeding arteries of PAVMs. Follow-up CE-MRA showed 57 newly developed PAVMs in 14 patients (interval 1- 6 years), and 32 reperfused PAVMs (due to recanalization, insufficient packing) in 24 patients (interval 3 months-7 years) of which 5 patients



CE-MRA global DSA superselective DSA
 Reperfused PAVM

where embolized elsewhere. All reperfused PAVMs were confirmed by DSA and successfully reembolized. Especially in reperfused PAVMs, DSA frequently only demonstrated flow in the AVM after selective catheterization of the feeding vessel. 47 of 286 patients (16,5%) showed involvement of the liver on MR imaging. Regarding MRI of the brain cerebral AVMs were only found in 16 patients.

Conclusion: CE-MRA should be the method of choice for management of PAVMs in HHT patients. Advantages of CE-MRA include lack of ionizing radiation, high sensitivity in detection of clinically relevant PAVM and the possibility of detecting reperfused AVMs in case if platinum coils were used for embolization. Lack of ionizing radiation is of special interest in HHT-patients, since often first interventions in PAVMs are performed in young adults and regular follow-up studies are mandatory. Using CT for screening would result in an unacceptable accumulated radiation dose. Furthermore, beam-hardening artifacts in CT due to embolization material deteriorate image quality and the possibility to detect reperfused PAVMs.