

## Feasibility of mitral valve blood flow quantification by 7D PC-SSFP

Marijn P Rolf<sup>1</sup>, Mark BM Hofman<sup>1</sup>, Joost PA Kuijjer<sup>1</sup>, Rob J van der Geest<sup>2</sup>, Aernout M Beek<sup>3</sup>, Albert C van Rossum<sup>3</sup>, and Rudolf M Verdaasdonk<sup>1</sup>

<sup>1</sup>Physics and Medical Technology, ICaR-VU, VU University Medical Center, Amsterdam, Netherlands, <sup>2</sup>Radiology, Leiden University Medical Center, Leiden, Netherlands, <sup>3</sup>Cardiology, ICaR-VU, VU University Medical Center, Amsterdam, Netherlands

**Introduction:** Blood flow assessment of mitral valvular flow is important in the clinical management of patients with mitral valvular regurgitation. Accurate measurements of the regurgitant volume will thus support clinical decision making on treatment. It is possible to quantify the mitral regurgitant volume indirectly by the difference of the ejection volume through the aorta and the morphological left ventricular stroke volume. Direct measurement of mitral regurgitation is still a topic of research. The main challenges herein are continuous movement of the valve through the cardiac cycle, high velocity jets causing signal voids, and image contrast within the heart for these measurements. 7D PC-SSFP has a benefit of improved contrast to visualize the valve plane directly [2].

This study investigated the feasibility of using a SSFP-based phase contrast sequence for mitral regurgitation assessment. The new 7D PC-SSFP sequence was compared to the indirect measurement and the more standard 7D PC-GE technique.

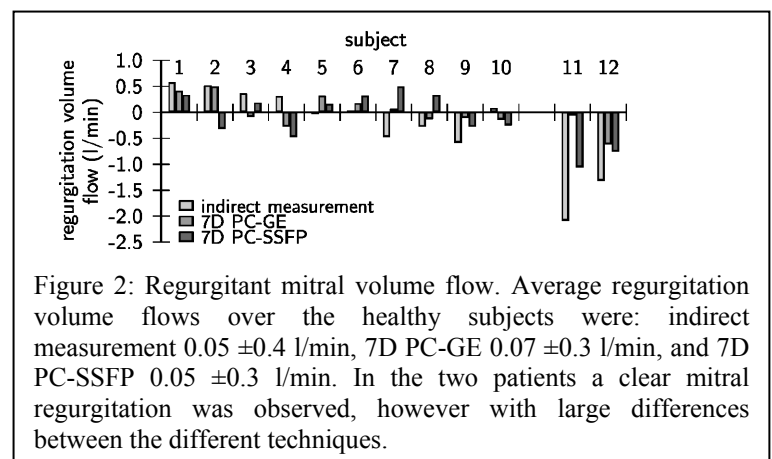
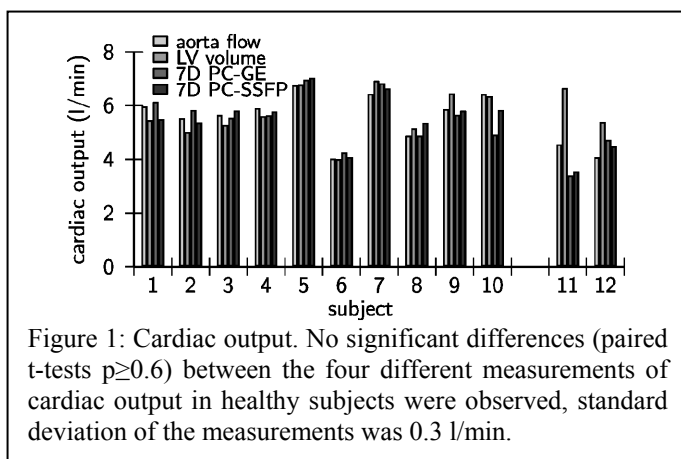
**Method:** The 7D PC-SSFP sequence is based on a regular 3D balanced SSFP gradient scheme with velocity encoding. The sequence was previously introduced for 2D imaging [1] and validated for cardiac flow quantification with a single velocity encoding direction [2]. In this study, the SSFP sequence was implemented with 3D spatial imaging and velocity encoding in three orthogonal directions.

Ten healthy volunteers and two patients with mitral regurgitation were scanned. In each subject the volume flow through the mitral valve was assessed with three different methods: 1) indirectly using aortic flow and left ventricular volume difference, 2) directly at the mitral valve using a 7D PC-GE sequence, and 3) directly at the mitral valve using the new 7D PC-SSFP sequence.

Imaging parameters were: 7D PC-GE: spatial resolution 1.3x1.3x5 mm<sup>3</sup>, matrix 256x208x10, FOV 320x260x50 mm<sup>3</sup>, TR/TE 9.9/6.3 ms, Venc 150 cm/s, non segmented, excitation angle 10°, BW 260 Hz/pix, temporal resolution 39.7 ms, ECG retrogating, parallel imaging factor 4 (GRAPPA); duration 12 minutes @60bpm. 7D PC-SSFP: spatial resolution 1.8x1.8x5 mm<sup>3</sup>, matrix 192x156x10, FOV 340x276x50 mm<sup>3</sup>, TR/TE 5.7/2.3 ms, Vmax 150 cm/s, 6 segments, excitation angle 70°, BW 900 Hz/pix, temporal resolution 34.4 ms, ECG retrogating, no parallel imaging, and a locally adjusted shim; duration 26 minutes @60bpm. The measurements at the level of the mitral valve were planned using a four-chamber view.

All image analysis was performed using Mass (v2011-EXP, Leiden, the Netherlands). Contours were drawn on the magnitude images, after which the average volume flow through the area at every phase in the cardiac cycle was determined. The blood flow due to valvular motion was calculated from the slice displacement multiplied by the valve area. From the flow curves cardiac output was calculated by integration of the volume flow over the whole cardiac cycle. Direct quantification of the regurgitant volume flow was performed by integration only during systole. The differences between the methods were tested using a paired Student's t-test.

**Results:** First image results showed reasonable image quality, however, the images of some subjects with pronounced chest breathing suffered from respiratory motion. The results from cardiac output measurements and regurgitation volume flows by the different methods in healthy subjects (1 to 10) and two patients with mitral insufficiency (subjects 11 and 12) are presented in Figures 1 and 2.



**Discussion:** The new 7D PC-SSFP method showed feasible to measure directly the mitral valvular regurgitation volume. In healthy subjects the outcome was comparable to the 7D PC-GE and the indirect method. And regurgitation volumes were not significantly different from zero. In patients, the 7D PC-SSFP acquisition measured a clear regurgitation. Further research in a more extensive patient group should be performed to assess beneficial value of the new technique. Before such a study, the 7D PC-SSFP method should be optimized, amongst others with parallel imaging and respiratory gating.

**References:** [1] Overall WR et al. MRM 2002;48:890-898, [2] Rolf MP et al JMRI 2009;30:947-955.