

## Pathologies of acute optic neuritis in EAE mice assessed using diffusion MRI and myelin water

Peng Sun<sup>1</sup>, Yong Wang<sup>1</sup>, Ying-Jr Chen<sup>2</sup>, Anne Cross<sup>3</sup>, and Sheng-Kwei Song<sup>1</sup>

<sup>1</sup>Radiology, Washington University in St. Louis, Saint Louis, MO, United States, <sup>2</sup>Chemistry, Washington University in St. Louis, Saint Louis, MO, United States,

<sup>3</sup>Neurology, Washington University in St. Louis, Saint Louis, MO, United States

### Introduction

Multiple sclerosis (MS) is an inflammatory demyelinating disease of the central nervous system (CNS). It is the second leading cause of neurological disability in young adults. Optic neuritis is often the first symptom of MS. It starts with inflammation leading to demyelination and eventually axonal loss, although the exact sequence is not fully clear. Complicated pathologies are involved in optic neuritis, including edema, demyelination, gliosis, and inflammation<sup>[1]</sup>. DTI has been demonstrated to reflect the optic nerve axonal and myelin damage and predict function in optic neuritis patients<sup>[2]</sup>. However, inflammation associated cell infiltration and vasogenic edema confound DTI findings, measurements of which focus on anisotropic white matter tracts. In the present study, a newly developed diffusion basis spectrum imaging (DBSI)<sup>[3]</sup> was employed to resolve the complex pathologies in optic nerves in mice with an animal model of MS, experimental autoimmune encephalomyelitis (EAE). The Carr-Purcell-Meiboom-Gill (CPMG)-T<sub>2</sub> was also employed to estimate the extent of demyelination by measuring myelin water fraction (MWF) of the nerve.

### Material and Method:

**Animal Model:** Adult SJL mice (n = 10) were separated into 2 groups: 5 in the experimental group and 5 in the sham group. Mice in the experimental group were immunized with PLP<sub>139-151</sub> peptide. At 13 or 14 days after immunization, mice reached first peak of clinical score (CS = 3.8±0.6). At peak CS, mice were perfusion fixed with phosphate buffered saline (PBS) followed by 4% paraformaldehyde in PBS. The intact brain was excised, placed in 4% paraformaldehyde/PBS for 2 weeks and transferred to PBS for storage at 4 °C. Optic nerves were carefully isolated 24 hours before MRI scans and stored in PBS before and after MR examinations.

**MRS:** A diffusion-weighted spin-echo spectroscopy sequence was employed to acquire diffusion weighted data with 99-direction diffusion encodings. A maximum diffusion weighting factor of b = 3200 s/mm<sup>2</sup> was employed. Other acquisition parameters were: 2s repetition time (TR), 11 ms echo time (TE), ms between gradient pulses (Δ), 7 ms gradient pulse duration (δ), 4 averages, 32gauss/cm maximum diffusion strength. The total acquisition was around 15 minutes.

The transverse relaxation decay curves were acquired using a 300-echo CPMG sequence with an inter-echo spacing of 0.5 ms. The sequence repetition time was 2s and the acquisition time was around 15 minutes.

**Data Analysis:** DTI and DBSI calculations were performed from the same diffusion-weighted data. The T<sub>2</sub> spectrum was accomplished using the non-negative least squares algorithm (NNLS). The different T<sub>2</sub> components were identified in the spectrum. Each component population was determined by summing the grid point amplitudes while the T<sub>2</sub> value was determined by a weighted average of each peak.

### Results and Discussions

Both DTI and DBSI derived radial diffusivity significantly increased in EAE group, suggesting demyelination at the first peak of EAE (Fig. 1A and 1B). Interestingly, there was no axon damage at this point, according to both DTI and DBSI derived axial diffusivity (data not shown). MWF decrease in EAE group confirms the demyelination observed by DTI and DBSI. DBSI derived water ratio increased by ~ 2 folds in EAE optic nerves reflecting vasogenic edema likely relating to inflammation at this stage (Fig 1C). This vasogenic edematous water component with increased diffusivity caused overestimation of demyelination based on DTI-derived radial diffusivity as compared with that derived by DBSI. The decreased MWF in EAE observed herein is likely a combined effect of vasogenic edema and demyelination. In conclusion, the current results suggest that DBSI may be used to identify and quantitate demyelination, as well as inflammation-related vasogenic edema. DBSI holds promise to resolve inflammation and edema, factors which have confounded DTI interpretation.

**References:** [1] Guttman, C.R.G et al. AJNR 1995. [2] Naismith et al. Neurology, 2009. [3] Wang, Y. et al. *Brain*. 2011, In Press.

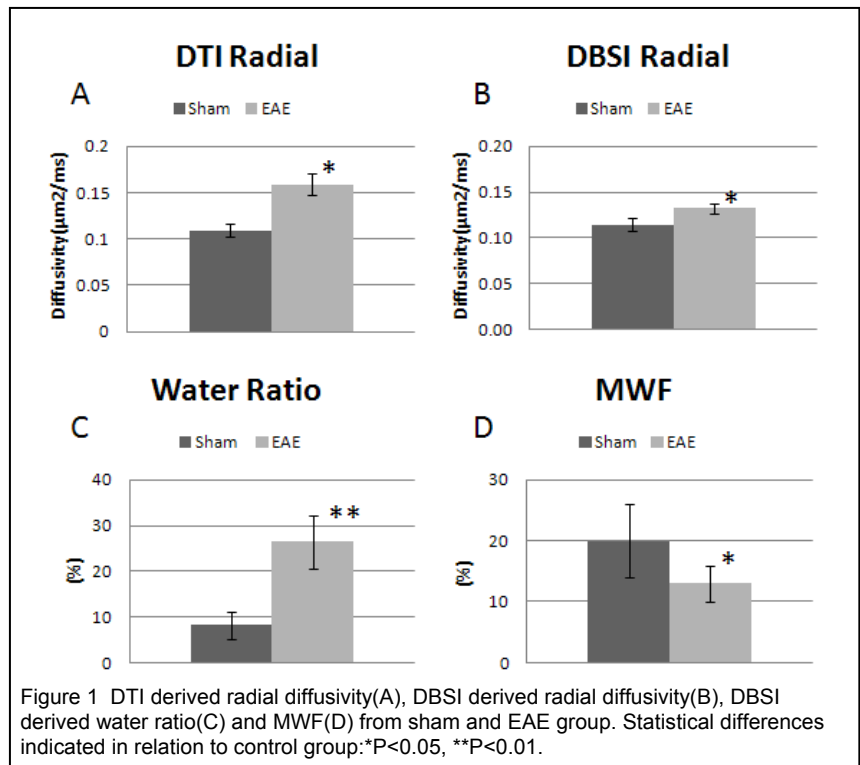


Figure 1 DTI derived radial diffusivity(A), DBSI derived radial diffusivity(B), DBSI derived water ratio(C) and MWF(D) from sham and EAE group. Statistical differences indicated in relation to control group:\*P<0.05, \*\*P<0.01.