

THE CORTICAL SIGNATURE OF AMYOTROPHIC LATERAL SCLEROSIS

Paola Valsasina¹, Federica Agosta¹, Nilo Riva², Massimiliano Copetti³, Michele Perini⁴, Alessandro Prelli⁵, Domenico Caputo⁶, Fabrizio Salvi⁷, Maria José Messina², Giancarlo Comi², and Massimo Filippi¹

¹Neuroimaging Research Unit, Institute of Experimental Neurology, San Raffaele Scientific Institute and Vita-Salute San Raffaele University, Milan, Italy, Italy, ²Department of Neurology, San Raffaele Scientific Institute and Vita-Salute San Raffaele University, Milan, Italy, Italy, ³Biostatistics Unit, IRCCS-Ospedale Casa Sollievo della Sofferenza, San Giovanni Rotondo, Italy, ⁴Department of Neurology, Ospedale di Gallarate, Gallarate, Italy, ⁵Neurologic Unit, Azienda Ospedaliera Fatebenefratelli e Oftalmico, Milan, Italy, ⁶Department of Neurology, Scientific Institute Fondazione Don Gnocchi, Milan, Italy, ⁷Department of Neurology, Ospedale di Bellaria, Bologna, Italy

Introduction. In amyotrophic lateral sclerosis (ALS), there is an urgent need for the development of robust biomarkers for an accurate diagnosis and prognosis. The measure of cortical thickness is a relatively new procedure for assessing the topography of brain damage in ALS [1], and is likely to be sensitive to regional cortical alterations in relation to the variable clinical progression of ALS patients.

Objective. Aim of this study was to determine whether ALS is associated with a cortical signature of thinning in specific motor and extra-motor regions, and to investigate whether a greater degree of regional cortical thinning is associated with the rate of disability progression.

Methods. 3D-T1 magnetization prepared rapid acquisition gradient echo (MP-RAGE) images were acquired from 44 ALS patients and 26 healthy controls. Cortical reconstruction and thickness estimation was performed with the Freesurfer image analysis suite (<http://surfer.nmr.mgh.harvard.edu/>). Thickness measures from 74 cortical and subcortical regions of interest (ROI) per hemisphere were generated, as described in Destrieux et al. [2]. Vertex-by-vertex and ROI-based group differences in cortical thickness, as well as age-by-group effects, were assessed using linear models. The discriminatory ability of MRI variables in distinguishing patients from controls was estimated using the Concordance Index (C index) and a logistic regression analysis. Correlations between cortical thickness measures and disease progression rate were estimated using the Pearson coefficient.

Results. Vertex-by-vertex analysis showed significant differences between the ALS group and controls in the superior part of the left precentral sulcus, left paracentral gyrus, and right precentral gyrus (Figure 1)

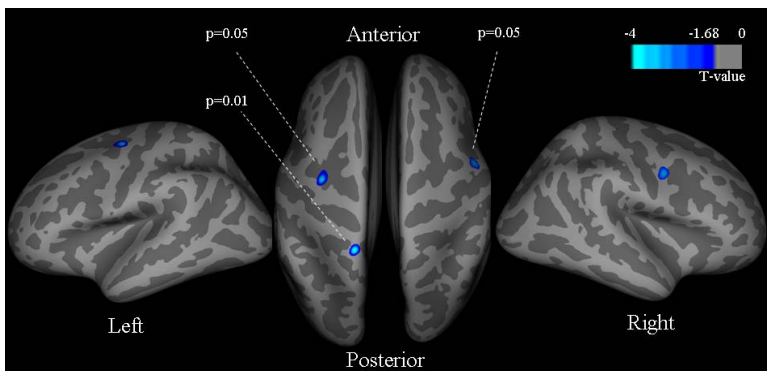


Figure 1.

Vertex-based significant differences of cortical thickness between controls and ALS patients ($p < 0.05$, uncorrected).

ROI-based analysis showed a widespread pattern of cortical thinning in ALS patients compared with controls, with a bilateral involvement of the sensorimotor cortex, prefrontal and ventral frontal cortices, cingulate gyrus, insula, superior and inferior temporal and parietal regions, and medial and lateral occipital areas. There was a significant age-by-group effect in the sensorimotor cortices bilaterally, suggesting a stronger association between age and cortical thickness measures in ALS patients compared to controls (Figure 2).

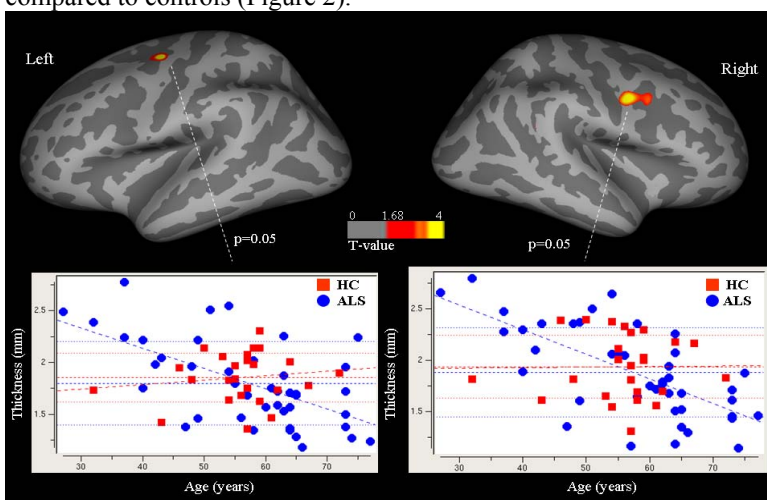


Figure 2.

Significant differences of association between cortical thickness and age in ALS patients vs. healthy controls (HC) ($p < 0.05$, uncorrected). These results seem to suggest a greater cortical thinning with increasing age in ALS patients compared with controls.

The mean cortical thickness of the sensorimotor, frontal and temporal cortices distinguished patients with ALS from healthy controls (C index > 0.65). Cortical thinning of the left sensorimotor cortices was related to a faster clinical progression ($r = -0.33$, $p = 0.03$).

Conclusions. ALS patients showed a distributed cortical thinning of motor and extra-motor regions, which might be an additional diagnostic marker in ALS. The thinning of the sensorimotor cortex might contribute to identify patients with a rapidly progressive disease course.

References. [1] Verstrate et al., PLOS One 2010; 27:e13664; [2] Destrieux et al., NeuroImage 2010;53:1-15.