

3D Neuromelanin-Sensitive MRI with Automated Volume Measurement of Substantia Nigra Pars Compacta for the Diagnosis of Parkinson's Disease

Kimihiko Ogisu¹, Kosuke Kudo², Makoto Sasaki², Ken Sakushima³, Satoshi Terae⁴, Mitsuhiro Nakanishi⁵, Shunrou Fujiwara⁶, and Hiroki Shirato¹

¹Graduate School of Medicine, Hokkaido University, Sapporo, Hokkaido, Japan, ²Advanced Medical Research Center, Iwate Medical University, ³Department of Neurology, Hokkaido University Hospital, ⁴Department of Radiology, Hokkaido University Hospital, ⁵Hokkaido University Hospital, ⁶Department of Neurosurgery, Iwate Medical University

INTRODUCTION: Parkinson's disease (PD) is a degenerative disorder of dopaminergic neurons in the substantia nigra pars compacta (SNc). The diagnosis of PD mainly depends on the clinical findings, and the role of imaging studies, including MRI, is limited for excluding other brain disorders. Dopaminergic neurons contain a black pigment called neuromelanin, which has paramagnetic T1-shortening effects [1]. Therefore, neuromelanin-sensitive MRI can be obtained using a T1-weighted sequence for detecting neuromelanin in the SNc and locus ceruleus [2]; the technique can distinguish PD patients from healthy volunteers. However, most of the previous reports used 2D fast spin echo (FSE) technology, which provides subjective measurements because objective measurements are difficult due to signal inhomogeneity in 2D acquisition. We assumed that 3D acquisition than 2D acquisition might be more suitable for neuromelanin-sensitive MRI to obtain more homogenous signals and more objective volume measurements. The aim of this study is to distinguish PD patients from healthy volunteers by obtaining automated and objective measurement of the SNc by using 3D neuromelanin-sensitive MRI.

MATERIALS AND METHODS: We examined 26 PD patients and 26 age-matched healthy volunteers. The average Hoehn-Yahr stage, United Parkinson's Disease Rating Scale, and period of illness in PD patients were 2.3, 29.0, and 7.2 years, respectively. A 3T MRI unit (Signa Excite HDx; GE Healthcare) was used to obtain neuromelanin-sensitive MRI with a 3D fast gradient echo technique (repetition time, 22 ms; echo time, 2.4 ms; flip angle, 20°; field of view, 220 mm; matrix size, 512 × 320; slice thickness, 2.5 mm; and partial magnetization transfer pulse). After normalizing the signal intensity of decussation of the superior cerebellar peduncle, SNc volume was automatically measured using a modified version of Perfusion Mismatch Analyzer (version 3.3.0.4). The region-growing technique was used to define volume of interest (VOI) and seeding point. SNc volume was automatically recorded at various signal thresholds (relative signal of decussation of the superior cerebellar peduncle was used as the threshold). The average volume of PD patients and healthy volunteers was compared using a t-test at the same threshold. The best threshold to distinguish between both the groups was defined when the p value of the t-test reached a minimum. At the best threshold, receiver operating characteristic (ROC) analysis was performed to determine sensitivity, specificity, and Az values with an optimum cutoff value to distinguish PD patients from healthy volunteers. SPSS Statistics version 18 (SPSS; Chicago, Ill) was used for all the statistical tests.

RESULTS: For all the thresholds of VOI, the SNc volume of PD patients was significantly smaller than that of the healthy volunteers (Fig. 1). The best threshold was 1.81, at which the p value was minimum ($p = 0.007$, student t test). At the best threshold, the average SNc volumes of PD patients and healthy volunteers were $0.47 \pm 0.14 \text{ cm}^3$ and $0.59 \pm 0.17 \text{ cm}^3$, respectively. In the ROC analysis, the optimal cutoff value was 0.52 cm^3 , in which the sensitivity, specificity, and Az were 0.69, 0.62, and 0.71, respectively (Fig. 2).

DISCUSSION We demonstrated the feasibility of 3D acquisition of neuromelanin-sensitive MRI and objective measurement of SNc volume was achieved thanks to the signal stability between slices. The SNc volume measured by neuromelanin-sensitive MRI was significantly smaller in PD patients than in healthy volunteers, indicating degeneration of dopaminergic neurons in the substantia nigra. This result suggests that our method can be used to diagnose PD. However, sensitivity, specificity, and Az were not satisfactory in comparison to the previously reported 2D method [3-5]. This is probably because ferrous accumulation [6] in the SNc affects signal intensity more in the 3D gradient echo sequence than in 2D FSE. Further optimizations of the scan protocol and analysis methods are needed to improve PD diagnostics.

CONCLUSION 3D neuromelanin-sensitive MRI with automated volume measurement can objectively distinguish PD patients from healthy volunteers.

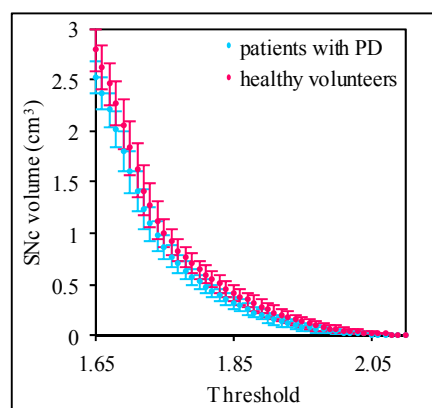


Fig. 1 SNc volume versus threshold of volume of interest (VOI). Thresholds ranged from 1.65 to 2.1.

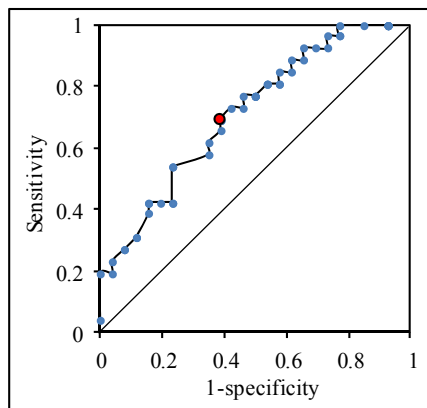


Fig. 2 Sensitivity and specificity using the 3D method

REFERENCES

- [1] W. Scott Enochs, et al. Radiology 1997;204:417-423.
- [2] M. Sasaki, et al. Clin Neuroradiol 2008;3:147-153.
- [3] M. Sasaki, et al. NeuroReport 2006;17:1215-1218.
- [4] E. Shibata, et al. Magn Reson Med Sci 2006;5:197-200.
- [5] E. Shibata, et al. Biol Psychiatry 2008;64:401-406.
- [6] E. Sofic, et al. J Neurochem 1991;56:978-982.