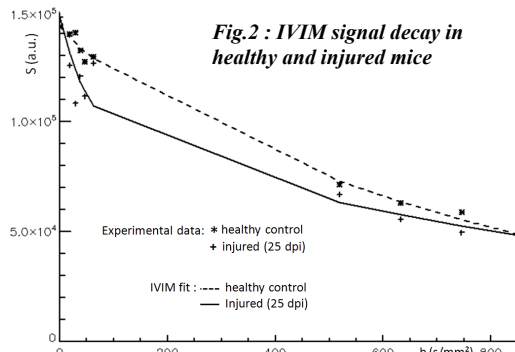



Intra Voxel Incoherent Motion (IVIM) MRI: an alternative method to get spinal cord (SC) vascular description. Preliminary results in healthy and injured mice.

Virginie Callot¹, Guillaume Duhamel¹, Jérôme Laurin², André Mauès de Paula³, and Patrick J Cozzone¹

¹CRMBM, CNRS, Aix-Marseille Univ, Marseille, France, ²ISM, CNRS, Aix-Marseille Univ, Marseille, France, ³Service d'Anatomie Pathologique, Hôpital de la Timone, AP-HM, Marseille, France

INTRODUCTION: Blood perfusion plays a crucial role in spinal cord injury (SCI). It is involved in posttraumatic processes (with altered vessels and ischemia leading to secondary damage) [1,2] and in endogenous repair processes (with angiogenesis supporting axonal and neuronal regeneration) [3]. Although important, *in vivo* MR measurements of SC hemodynamics are scarce. Few studies have already been proposed, based on dynamic contrast enhancement [4], vascular-space-occupancy [5] or arterial spin labeling (ASL) [6] techniques. However these methods are not yet available in all scanners.



In this context, the present study was undertaken to evaluate the potentiality of the Intra Voxel Incoherent Motion (IVIM) technique [7]. IVIM is a diffusion-based method that can easily be performed in most scanners with conventional imaging or EPI read-out and which has already been successfully applied to collect perfusion indices in moving organs [8,9] or low-perfused tissue [10]. IVIM could thus be a promising alternative to collect information about the SC vascular status.

METHOD: Experiments were conducted on anesthetized healthy mice (n=5), on an 11.7T Bruker scanner, using a volume coil and a Stejskal-Tanner diffusion sequence (10 b-values ranging from 0 to 700 s/mm², 2 directions (parallel (//) and perpendicular (⊥) to the SC axis (fig.1)). Image acquisitions were synchronized with respiration.

The IVIM protocol was applied in an injured mouse model (PSI impactor, C3 level, left lateral), along with spinal cord blood flow (SCBF) measurements performed with Arterial Spin Labeling (FAIR-QUIPSII ASL technique) [6,11]. IVIM indices and SCBF values were measured at days 8, 15, 25 and 30 post-injury (dpi). The mouse was then sacrificed for immunohistochemistry analyses. Whereas conventional diffusion signal follows the equation $S=S_0 \cdot \exp(-b \cdot \text{ADC})$, with S_0 the signal amplitude for $b=0$ s/mm² and ADC the apparent diffusion coefficient (mm²/s), the IVIM signal decay (fig.2) is given by: $S=S_0 \cdot [(1-f) \cdot \exp(-b \cdot D) + f \cdot \exp(-b \cdot (D+D^*))]$, with f a vascular fraction related to the amount of active capillaries (%), D the water diffusion coefficient and D^* a flow or velocity index (mm²/s). In a first approach, D , f and D^* were calculated by a segmented analysis [9], in regions of interest (ROI) located in the ventro-lateral white matter (vWM) and ventral gray matter (vGM).

RESULTS: For healthy mice, ADC was significantly higher than D , in both GM (data not shown) and WM (fig.3, control), demonstrating a vascular contribution in the diffusion measurement. f was found equal to 8% in WM and 10% in GM (fig.4a, control), and D^* equal to $5.4 \cdot 10^{-3}$ mm²/s in WM and $5.6 \cdot 10^{-3}$ mm²/s in GM (fig.4b, control). For the injured mouse, ADC was also higher than D (fig.3). The evolution of D values indicated fiber disruption ($D \downarrow$) in the early days, and then gliosis ($D \uparrow$). Fig.4 shows the posttraumatic evolution of the vascular parameters (f , D^* and SCBF) in both GM and WM. The visible vascular fraction, f , did not show significant changes during the first 2 weeks, however it dramatically increased during the 3rd week, especially in WM. This was attributed to angiogenesis and confirmed by histology, which demonstrated a significant increase of the number of vessels in the WM lesion compared to control mice. D^* and SCBF values, after an initial drop due to ischemia during the 1st week, increased significantly. These hemodynamic patterns were characteristic of neuronal regeneration and tissue repair [3,12]. Fig.5 shows the evolution of the SCBF values as a function of D^* during the posttraumatic follow-up. A fairly good correlation was found between the 2 parameters.

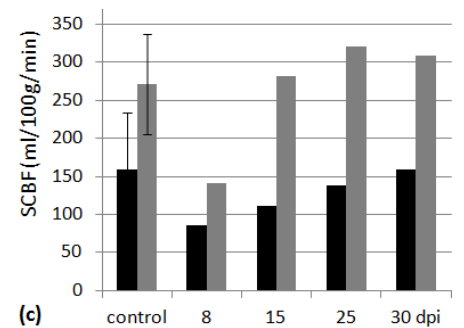
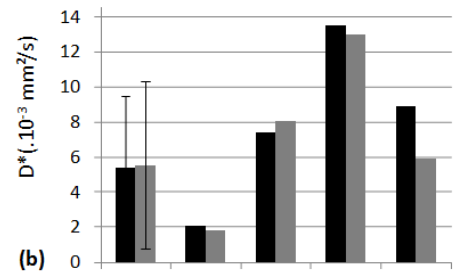
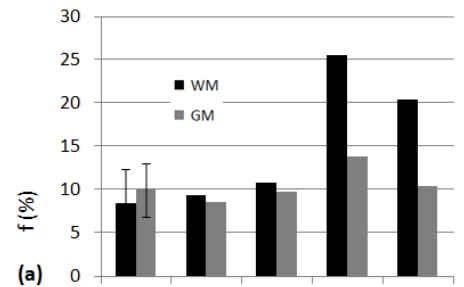
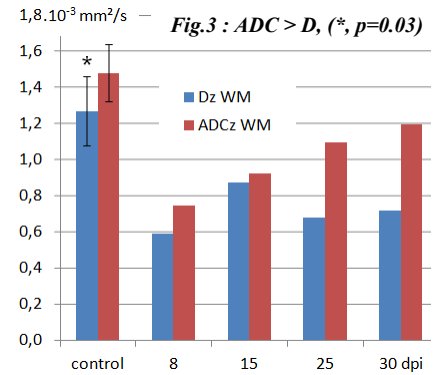
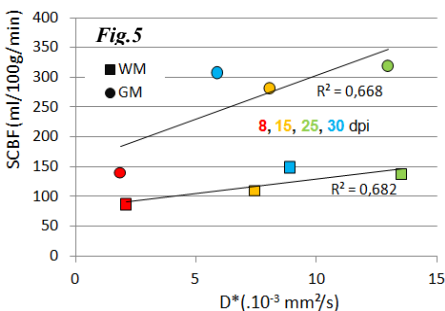


Fig.4: Posttraumatic evolution of (f , D^* , SCBF).

DISCUSSION: The IVIM method allowed assessment of diffusion and perfusion indices at the same time. For injured mouse, the evolution of the vascular IVIM indices were correlated with SCBF values and confirmed by histology analyses. Thus, although IVIM parameters did not directly described perfusion, this study demonstrated its potentiality in providing relevant vascular information. Further investigation and methodological improvements (including IVIM maps for low-perfusion regime) are worthy since IVIM may constitute an alternative method to get SC vascular descriptions and pathological characterizations.

REFERENCES: [1] Hall et al, *J Neurosurg* 1986, [2] Mautes et al, *Phys Ther* 2000, [3] Dray et al, *PNAS* 2009, [4] Bilgen et al, *MRM* 2001, [5] Lu et al, *NMR in biomed* 2008, [6] Duhamel et al, *MRM* 2008, [7] LeBihan et al, *Radiology* 1986, [8] Luciani et al, *Radiology* 2008, [9] Callot et al, *MRM* 2003, [10] Karampinos et al, *JMRI* 2010, [11] Duhamel et al, *MRM* 2011, [12] Zhang et al., *Exp Neurol* 1997.