

## Early Alzheimer's Disease: Does Gray Matter Loss Pattern Correlate With Naming Impairment?

M. Vittoria Spampinato<sup>1</sup>, Ryan Parker<sup>2</sup>, Karen Elizabeth Patrick<sup>2</sup>, Zoran Rumboldt<sup>1</sup>, Jacobo Mintzer<sup>3</sup>, and Hrvoje Vavro<sup>4</sup>

<sup>1</sup>Radiology and Radiological Science, Medical University of South Carolina, Charleston, SC, United States, <sup>2</sup>Medical University of South Carolina, Charleston, SC, United States, <sup>3</sup>Neurosciences, Medical University of South Carolina, Charleston, SC, United States, <sup>4</sup>Diagnostic and Interventional Radiology, University Hospital Dubrava, Zagreb, Croatia

### Purpose

Our objective was to compare patterns of gray matter (GM) volume loss in subjects with newly diagnosed Alzheimer's disease (AD) with and without word retrieval impairment.

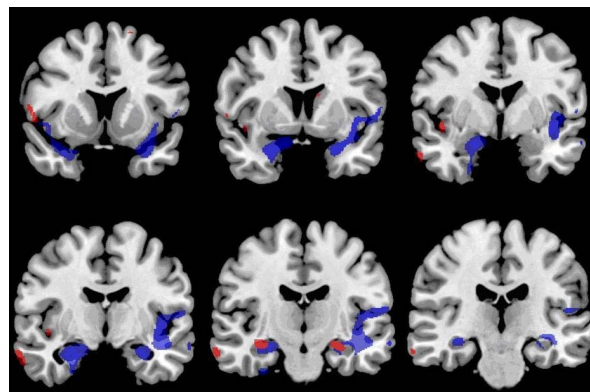
### Materials & Methods

Seventy-six subjects (32 women, 44 men; mean age 76 ±7) from the Alzheimer's Disease Neuroimaging Initiative (ADNI) cohort with progression from amnesic mild cognitive impairment (aMCI) to AD during study participation were included. Disease severity was assessed using the Clinical Dementia Rating (CDR) scale and CDR Sum of Boxes. Word retrieval performance was evaluated using the 30-item Boston Naming Test (BNT) (median score was 25, range 7-30). Forty-one subjects had BNT score equal or above the median (high BNT group), whereas thirty-five subjects had BNT score lower than the median (low BNT group). Comparison of demographic characteristics and disease severity between groups was done by Pearson  $\chi^2$  test, one-way Anova, and General Linear Model Repeated Measures.

Brain MRI T1 MPRAGE images obtained at the time of AD diagnosis and 12 months later were available for each patient. The images were processed using voxel-based morphometry (VBM) with Statistical Parametric Imaging (SPM5). Longitudinal imaging data comparison was done by paired t-tests; results were significant if the p-value was smaller than 0.05 with family wise error rate correction (FWER) for multiple comparisons.

### Results

Demographics and disease severity did not differ significantly between the two groups. However, longitudinal analyses revealed different distribution and severity of GM volume loss in patients with and without word retrieval impairment. Low BNT subjects demonstrated overall greater GM volume loss with greater involvement of the left hemisphere, specifically left temporal, frontal, parietal lobe and insula, as well as right frontal and parietal lobe. In the high BNT group loss of GM volume was bilateral, and involved the temporal and frontal lobes, left caudate nucleus and right insula. There was bilateral hippocampal volume loss in both low and high BNT groups.



Areas of GM volume loss in subjects with (blue) and without (red) word retrieval impairment

### Conclusion

In early AD GM volume loss patterns differ both in extent and distribution between patients with and without word retrieval impairment at the same disease stage. These findings have potential implications in prognosis and therapy of AD.