

## Early Alzheimer's Disease and Gray Matter Atrophy: is there a Gender Difference?

M. Vittoria Spampinato<sup>1</sup>, Markus Weinger<sup>2</sup>, Karen Patrick<sup>2</sup>, Ryan Parker<sup>2</sup>, and Hrvoje Vavro<sup>3</sup>

<sup>1</sup>Radiology and Radiological Science, Medical University of South Carolina, Charleston, SC, United States, <sup>2</sup>Medical University of South Carolina, <sup>3</sup>University Hospital Dubrava, Zagreb, Croatia

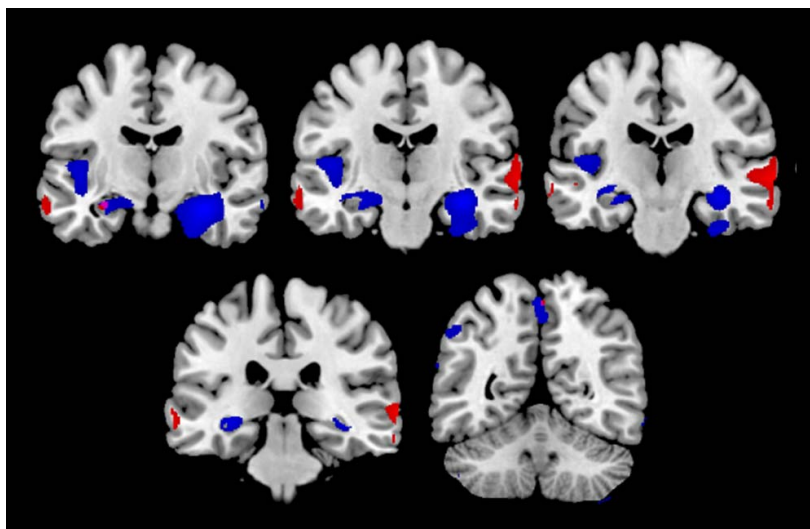
**Purpose:** Our aim was to assess if there are gender specific differences in gray matter (GM) volume loss patterns in patients with newly diagnosed Alzheimer's disease (AD) using voxel-based morphometry.

**Methods:** Our study population included 83 patients (52 men, 31 women; mean age  $77 \pm 7$  years) from the Alzheimer's Disease Neuroimaging Initiative (ADNI) cohort, who during study participation experienced progression from amnesic mild cognitive impairment (aMCI) to AD. Imaging and clinical evaluation of aMCI patients were obtained every six months as part of the ADNI protocol. Brain MRIs obtained one year before conversion from aMCI to AD, at the time of AD diagnosis, and after twelve months were available. Voxel-based morphometry with SPM5 was used to process MPRAGE images. The General Linear Model Repeated Measures was performed to evaluate for differences over time in disease severity, measured using the Clinical Dementia Rating (CDR) scale and CDR Sum of Boxes. Comparison between longitudinal imaging data was conducted using two-sample and paired t-tests. Results were considered significant when the p-value  $< 0.05$  after family wise error rate correction (FWER) for multiple comparisons.

**Results:** There was a significant progressive cognitive decline in both males and females ( $p < 0.001$ ) without significant interaction between CDR and gender. Baseline group comparison showed significant greater atrophy in the posterior cingulate gyrus in females than males.

Longitudinal analyses revealed gender specific differences in GM volume loss during the 12 months before AD diagnosis (women: bilateral uncus; men: right inferior frontal lobe; left inferior frontal lobe; right uncus;) and during the 12 months after AD diagnosis (women: left hippocampus; left superior and middle temporal gyrus; right superior and inferior temporal gyrus; right gyrus rectus; right superior parietal lobule; men: bilateral hippocampus and right parahippocampal gyrus; left insula; left superior frontal gyrus; left inferior parietal lobule; left precuneus, left caudate).

**Conclusions:** Our data indicate that the extent and distribution of regional gray matter volume loss in patients with AD is strongly influenced by the gender. This finding has potential important implications for therapeutic approaches in AD and should be taken into consideration in clinical trials.



GM volume loss during the 12 months after AD diagnosis in men (blue) and women (red) (images displayed in neurological convention)