

# Mapping Plasticity in Rat Hippocampus After Prenatal Radiation Exposure Using MEMRI

Nai-Ying Kuo<sup>1,2</sup>, Yeu-Sheng Tyan<sup>1,3</sup>, and Jun-Cheng Weng<sup>1,3</sup>

<sup>1</sup>School of Medical Imaging and Radiological Sciences, Chung Shan Medical University, Taichung, Taiwan, <sup>2</sup>Department of Electrical Engineering, National Tsing Hua University, Hsinchu, Taiwan, <sup>3</sup>Department of Medical Imaging, Chung Shan Medical University Hospital, Taichung, Taiwan

## Introduction

Radiological and nuclear medicine examinations as well as radiotherapy during pregnancy have been associated with a slightly increased risk of brain tumor [1]. Radiation exposure during the embryonic period causes various diseases such as hydrocephalus, microcephaly, hippocampal atrophy and other brain disorder [2]. The radiation exposure induced hydrocephalus is responsible for dilatation of the cerebral ventricles and disruption of vascular endothelial cells [3]. Recently it has been demonstrated that manganese-enhanced magnetic resonance imaging (MEMRI) can be used to visualize neuroarchitecture [4]. MEMRI may also be useful in the evaluation of radiation-induced central nervous system (CNS) disorder. Therefore the goal of our study is to assess developmental CNS disorder induced by prenatal radiation exposure with MEMRI. Our results showed that changes in longitudinal relaxation time (T1) induced by intracellular Mn<sup>2+</sup> contrast agents and changes in volume were quantitatively observed in the hippocampal area, ventricles and entire brain of normal and radiation-exposed rats.

## Materials and Methods

A total of 15 Wistar rats weighing 400 - 450 g were used. Ten rats received a single exposure to whole body X-ray irradiation at a dose of 0.75 Gy and 1.5 Gy, respectively, on day 7 of pregnancy, while the other five were used as controls. Three months after birth, MRI scans were performed on the normal control (N=5) and radiation-exposed (N=5 for 0.75Gy and N=5 for 1.5Gy) progeny. MnCl<sub>2</sub> was given by intraperitoneally injecting 175 mg/kg of a 120 mM MnCl<sub>2</sub> solution. Rats were scanned 24 h after MnCl<sub>2</sub> administration. During the MR scanning, the rats were anesthetized with 2% isoflurane mixed with O<sub>2</sub>, maintained with 1.5% isoflurane. Rat body temperature was maintained at 37°C using warm water circulation.

The experiment was performed on a 1.5T MRI system (Sonata, Siemens MAGNETOM, Germany). A surface coil was used for RF reception. Three imaging sequences were performed to acquire T1W images. Multi-slice spin echo (SE) sequences w/ and w/o magnetization transfer contrast (MTC) were performed to obtain T1W images, TR/TE = 570/30 ms; in-plane resolution = 195µm x 390µm; slice thickness = 1.5 mm. Multi-slice spoiled gradient echo (GE) sequences w/ and w/o MTC were performed to obtain T1W images, TR/TE = 255/7.81 ms; flip angle = 70°; in-plane resolution = 260µm x 260µm; slice thickness = 1.5 mm. To improve detection sensitivity, magnetization prepared 180 degrees radio frequency pulses and rapid gradient echo (MPRAGE) T1W images was acquired, TR/TE/TI = 518/5.01/400 ms; in-plane resolution = 260µm x 260µm; slice thickness = 1.5 mm. A multi-slice fast spin echo sequence was also performed to obtain T2W images, TR/TE = 3760/114 ms; in-plane resolution = 195µm x 390µm; slice thickness = 1.5 mm.

ROIs encompassing the hippocampal area, ventricles and whole brain area were manually selected by a trained observer. The contrast enhancement at the hippocampus was quantified. The signal enhancement in the hippocampus was defined as the averaged signal in the ROI of hippocampus divided by it in the ROI of muscle tissue. The relative sizes of hippocampal area and ventricle were defined as the pixel numbers of hippocampal area divided by the pixel numbers of whole brain and the pixel numbers of ventricle divided by the pixel numbers of whole brain, respectively. ROI analysis and statistical calculations were performed using home-made Mathematica program and Excel add-in tools, respectively.

## Results and Discussions

In Fig. 1, our MEMRI results indicated spin echo, gradient echo and MPRAGE contrast-enhanced T1W images can clearly distinguish the hippocampal formation, CA1, CA2 and CA3 in the normal control rats. In the radiation-exposed rats, degeneration of the hippocampal formation was observed, but the CA2, CA3, and dentate gyrus were strongly enhanced by MnCl<sub>2</sub>. In contrast, CA1 was not enhanced which may due to its pyramidal-cell layer disappeared for radiation injured model. In Fig. 2, comparing with normal control rats, the manganese-enhanced signals calculated from all T1 contrast-enhanced images we used in the hippocampus (CA2, CA3, and dentate gyrus) of radiation-exposed model were significantly increased (p < 0.01, unpaired t-test). In Fig. 3, the size of hippocampal area of the radiation-exposed model were significantly decreased (p < 0.01, unpaired t-test). In Fig. 4 the size of ventricle of the radiation-exposed model was significantly increased (p < 0.01, unpaired t-test).

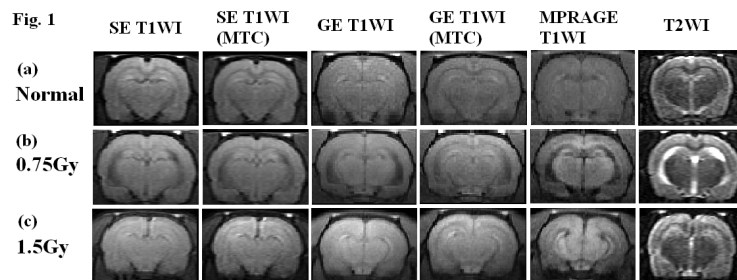
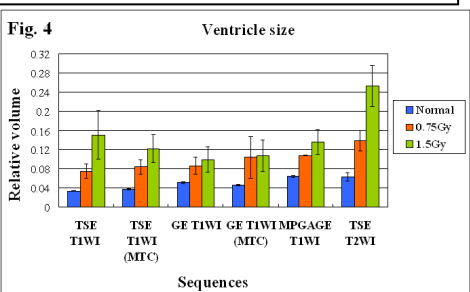
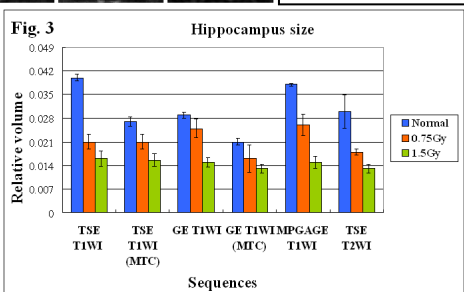
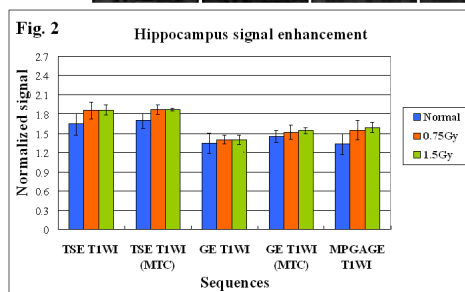


Fig. 1. Spin echo T1W images, spin echo T1W images with MTC, gradient echo T1W images, gradient echo T1W images with MTC, MPRAGE T1W images, and T2W images of (a) normal control rats, (b) 0.75 Gy radiation-exposed rats, and (c) 1.5 Gy radiation-exposed rats.  
Fig. 2. Signal enhancement in the hippocampus of normal control and radiation exposure models with different T1 contrast-enhanced sequences.  
Fig. 3. Relative sizes of hippocampal area of normal control and radiation exposure models with different pulse sequences.  
Fig. 4. Relative sizes of ventricle of normal control and radiation exposure models with different pulse sequences.



## Conclusions

Our results demonstrated that X-ray irradiation during the prenatal period showed a remarkable degeneration in brain formation, especially in the hippocampus and ventricle. The manganese-enhanced signal increased in the hippocampus (CA2, CA3, and dentate gyrus) in the radiation exposure model. It may due to hippocampal mossy fiber sprouting and astrogliosis. The atrophy of hippocampus and whole brain with ventricular dilatation could also be observed in the radiation-exposed model. In conclusion, quantitative MEMRI provides comprehensive multifunctional information for the evaluation and diagnosis of brain degeneration induced by prenatal radiation exposure.

## References

- [1] Janeczko K, et al., Brain Res 1997; 770: 237-241. [2] Sun XZ, et al., J. Radiat. Res. 2002 ; 43 : 89-98. [3] Pena LA, Cancer Res 2000; 60: 321-327. [4] Aoki I, et al., NeuroImage 2004; 22: 1046-1059.