

Longitudinal Diffusion Tensor Imaging Evaluation of Connectivity Changes in Rabbit External Capsules After Cerebral Hemisphere Radiation Exposure

Chao-Yu Shen^{1,2}, Wei-Ya Tseng¹, Chu-Wen Chang¹, Hsi-Chang Chang³, and Jun-Cheng Weng^{1,2}

¹School of Medical Imaging and Radiological Sciences, Chung Shan Medical University, Taichung, Taiwan, ²Department of Medical Imaging, Chung Shan Medical University Hospital, Taichung, Taiwan, ³Department of Radiation Oncology, Chung Shan Medical University Hospital, Taichung, Taiwan

Introduction

Cognitive impairment and gait disturbance are the major side effects of radiation-induced white matter injury. Magnetic resonance imaging (MRI) has been widely used as a noninvasive modality for detection of brain lesions, but the characterization of the normal brain tissue to therapeutic dose radiation is still not well understood [1]. The aim of our study was to longitudinally evaluate early-delayed radiation-induced changes of the brain white matter in a rabbit model after a single sub-lethal high dose irradiation (30 Gy) by using T2 weighted imaging (T2WI) and diffusion tensor imaging (DTI) [2, 3]. To quantify the diffusion anisotropy, fractional anisotropy (FA), mean diffusivity (MD), axial diffusivity (AD), and radial diffusivity (RD) were used. Results showed no significant change on T2WI but continuing decrease fractional anisotropy, early decreased axial diffusivity and late increased radial diffusivity in the follow-up time points. We suggested the DTI indices are more sensitive than T2WI and can reflect pathologic changes in radiation-induced brain white matter injury during early-delay phase.

Materials and Methods

Five male New Zealand rabbits of 1 year of age received irradiation of 30 Gy (collimations = 4 cm x 5 cm) to the right hemi-brain with a single highly collimated 6MV photon beam from a linear accelerator (Varian CL21EX) under anesthesia. Brain MRI examinations were performed before irradiation and at 1 week, 2 week, 4 week, 8 week and 12 week post irradiation with a 1.5T MR scanner (Magnetom Sonata, Siemens Medical Solutions, Erlangen, Germany), and double loop array coils were used. Whole brain coronal T2WI were obtained using the following parameters: repetition time (TR)/echo time (TE) = 4330/114 ms, resolution = 0.19 x 0.39 x 1.5 mm³, number of slices = 30. With number of excitation (NEX) = 13, the scan time was about 9.5 min. DTI data were acquired using a multi-slice, single-shot spin echo EPI sequence with the following parameters: TR/TE=2900/128 ms, resolution = 0.78 x 0.78 x 2 mm³, number of slices = 12 (contiguously from the genu of the corpus callosum to the end of the cerebrum). They were obtained using 12 diffusion-encoding directions with b values changing from 0 to 2,000 s/mm². With NEX = 9, the scan time was about 42 min.

In data analysis, FA, MD, AD and RD maps were first calculated from DTI data using DSI studio (National Taiwan University, Taiwan). Region of interests (ROIs) of the bilateral external capsules (EC) were drawn manually on three consecutive slices of T2WI and all DTI maps using imageJ (NIH, Bethesda, MD, USA) (Fig. 1a, 1b). Mean \pm standard error (SE) of image intensities of ROIs was then obtained. Ratios of injury EC/control EC of T2WI and DTI maps (e.g., FA_{IEC}/FA_{CEC}) were calculated for statistical analysis. Paired t-test was used to detect statistical differences between the pre- and the post-irradiation time points.

Results and Discussions

No statistically significant change in T2WI_{IEC}/T2WI_{CEC} could be observed at any time point. There was a continuing decrease in FA_{IEC}/FA_{CEC} at all the following time points (Fig. 2a), but the differences reached statistical significance only at 8th week (p=0.019) and 12th week (p=0.043) post irradiation. MD_{IEC}/MD_{CEC} and RD_{IEC}/RD_{CEC} appeared as a downward parabola and the vertex was around 8th week (Fig. 2b, 2c), but this was not reach statistical significance at any time point. AD_{IEC}/AD_{CEC} showed only a decrease at 1st week post irradiation but the difference was not reach statistical significance (Fig. 2d). Continuing FA reduction after brain irradiation in early-delayed phase can be explained by pathologic changes, including reactive astrogliosis, damage to the vasculature, edema and demyelination [3, 4]. It is more sensitive than T2WI and other DTI indices. Mild decreased first and then increased AD in early-delayed phase can caused by reactive astrogliosis, which processes of astrocytes wrapped bundles of fibers along the axonal pathway and result in initially interrupted and then amplified magnitudes of AD [3, 5]. Increased RD in late time points of early-delayed phase reflect destruction of white matter structure due to necrosis and demyelination. Decreased MD is the most sensitive measure for detecting cytotoxic edema from ischemia in acute phase (not demonstrated in our study), but in early-delay phase, MD changes reflect the result of mixed both AD and RD effects.

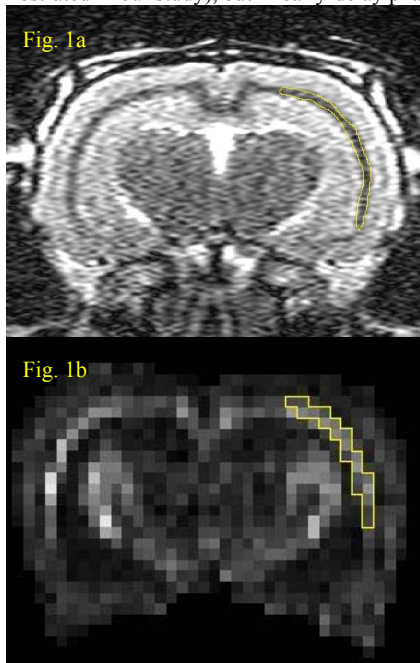


Fig. 1 Examples of ROIs (yellow line circled area) drawn manually on the right EC on T2WI (1a) and FA map (1b) using imageJ.

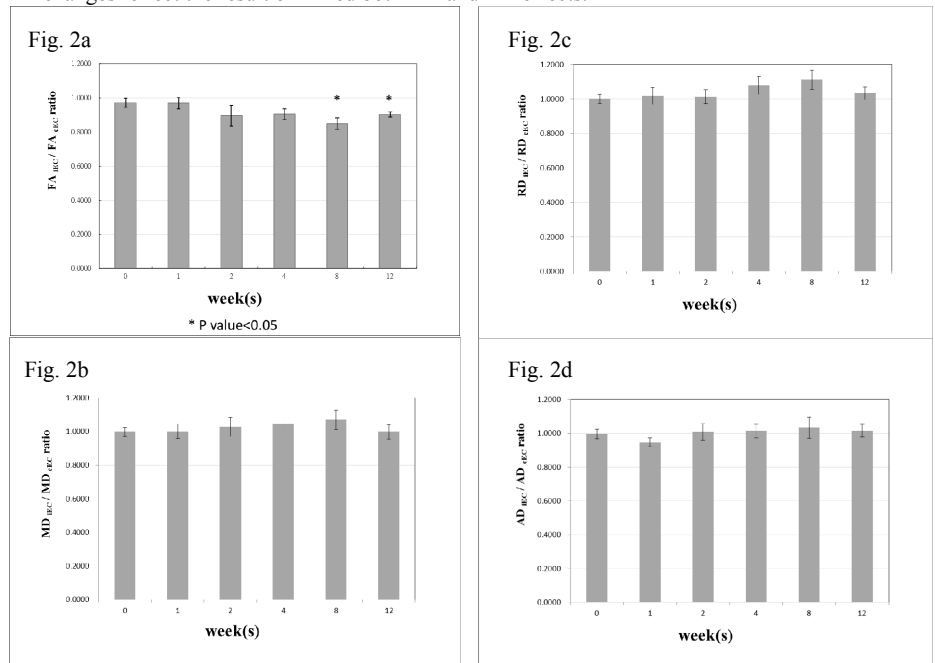


Fig. 2 Longitudinal changes of injury EC/control EC DTI indices including FA (2a), MD (2b), RD (2c) and AD (2d). Values between the pre- and the post-irradiation time points are compared with paired t-test. *, p < 0.05.

Conclusions

Our quantitative results suggested the DTI characteristics are more sensitive than T2WI and can reflect pathologic changes in radiation induced brain white matter injury during early-delay phase.

The authors would like to thank Zhen-Hui Li and Tao-Tao Chen for their assistance in the animal preparation.

References

- [1] Wang YX, et al. Radiology. 201; 254(1): 210-8. [2] Kennedy AS, et al. Invest Radiol. 1995; 30(4): 214-20. [3] Wang S, et al. Cancer Res. 2009; 69(3): 1190-8. [4] Leung LH, et al. Neuroimage. 2004; 21(1): 261-8. [5] Harsan LA, et al. J Neurosci Res. 200; 85(5): 935-44.