

# Automatic assessment of high grade brain tumour tissue in MR images: What is tumour and what radiation injury

Yaniv Gal<sup>1</sup>, Stephen Rose<sup>2</sup>, Pierrick Bourgeat<sup>3</sup>, Nicholas Dowson<sup>3</sup>, Zeike Taylor<sup>4</sup>, Michael Fay<sup>5</sup>, Paul Thomas<sup>5</sup>, Olivier Salvado<sup>3</sup>, and Stuart Crozier<sup>1</sup>

<sup>1</sup>School of Information Technology and Electrical Engineering, University of Queensland, Brisbane, Queensland, Australia, <sup>2</sup>Centre of Clinical Research, University of Queensland, Brisbane, Queensland, Australia, <sup>3</sup>CSIRO, Brisbane, Queensland, Australia, <sup>4</sup>Department of Mechanical Engineering, The University of Sheffield, Sheffield, United Kingdom, <sup>5</sup>Royal Brisbane and Women's Hospital, Brisbane, Brisbane, Queensland, Australia

## Background

Contrast enhanced MRI (CE MRI) is often used as the “gold standard” for high grade brain tumour (World Health Organisation [WHO] grade III and IV brain tumour) resection and radiotherapy planning. However, once a patient has gone through radio-chemo therapy, CE MRI provides limited accuracy in differentiating tumour recurrence from chemo-radiotherapy induced injury because both tissue types often yield significant contrast enhancement in CE MRI. Positron emission tomography (PET) imaging using tracers such as 4-dihydroxy-6-[18F]-fluoro-L-phenylalanine (FDOPA) has been shown to be clinically useful for detecting low grade and high grade brain tumours[1] with the limitations of low resolution and poor signal-to-noise ratio. Moreover, FDOPA PET does not suffer from the specificity limitation of showing radiation injured tissue as tumour tissue. This work tests the hypothesis that specificity of MRI to radio-injured high grade brain tumour tissue can be improved by utilising supervised classification techniques to estimate the probability of tumour tissue in each voxel in the MR image, independently (i.e. creating a “risk map”). The method is validated qualitatively against registered CE-MR and FDOPA-PET brain images.

## Materials and Methods

**Dataset:** Datasets from 10 patients (age range 47 to 71 years) with high grade brain tumour (WHO grade III or IV) were acquired for the study. Two of those has gone through tumour resection and received standard chemo-radio therapy. Three datasets were acquired from each of the two treated patients in three different time points: before resection (T1), 4 weeks post-resection post-therapy (T2), and 4 months post resection (T3). A T1 dataset was acquired from each one of other 8 patients as well. Each dataset included four MRI scans, all acquired in the same imaging session, namely a DCE MRI, ADC, and SWI map and an FDOPA PET scan. All MR images were acquired using a 3T Siemens TimTrio (Siemens, Erlangen, Germany) using standard sequences.

**Feature extraction:** prior to feature extraction all images of each dataset were registered to the 4<sup>th</sup> DCE-MRI post contrast volume. Then a kinetic model of enhancement (KME) [2] and a pharmacokinetic model (PKM) [3] were fitted to each contrast enhancement curve of each voxel, using non-linear Levenberg-Marquardt optimisation, and a set of ten features was extracted for each voxel in the image: Maximum KME enhancement time[4], Maximum KME relative enhancement [4], Contrast agent KME wash-in rate [4], Contrast agent KME wash-out rate [4], Area under the KME enhancement curve [5],  $K_{trans}$  (from PKM),  $V_e$  (from PKM),  $V_p$  (from PKM), ADC value and the Contrast Enhanced SWI (CE-SWI) value - normalised to yield maximum of 1 in the image.

**Classifier training and validation:** Following the feature extraction a training set of approximately 100 voxels (50 tumour, 50 benign) was selected from each T1 dataset. A manual delineation of the tumour was performed by an experienced nuclear-medicine physician for each dataset to assist with the selection of samples. A logistic regression classifier was then trained on the samples from all T1 datasets but one (of the treated patients), and was applied to all voxels in all time points of the ‘left-out’ patient. The process was repeated for each of the two radio-treated patients.

## Results

**Classifier validation:** As a preliminary stage the performance of the classifier was tested quantitatively on the tagged sample points using a leave-one-out strategy. The validation provided an area under the receiver operating characteristic (ROC) curve of  $0.85 \pm 0.01$  with minimum classification error of 0.2

**Tissue classification:** The resulting risk maps for the two patients were inspected qualitatively, by visually comparing the T2 risk map (where radio-injury is expected) with the corresponding FDOPA defined tumour extent. The underlying assumption was that tissue showing contrast enhancement in the CE-MRI but do not enhance in the FDOPA is likely to be radiation injured tissue and thus will also be classified as ‘low-risk’ by the classifier. Moreover, in T3, no recurrent tumour growth is expected in such region. The results are presented in **Error! Reference source not found.** showing that contrast enhancing tissue in the CE-MRI at T2 that is not correlated with FDOPA enhancement is indeed classified as ‘low-risk’ tissue by the classifier and does not indicate tumour regrowth in the T3 FDOPA images.

## Conclusions

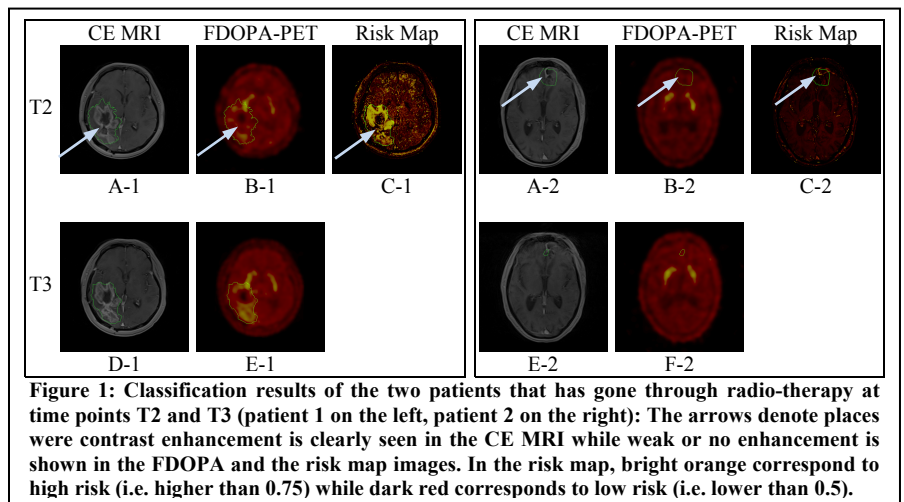
The results of experiment suggest that the risk maps generated from multiple MR images has the potential of differentiating between tumour tissue and radiation injury in post-therapy high grade brain tumour MR images.

## Acknowledgment

This work has been supported by a Queensland Government Smart State NIRAP grant (MedTeQ) and an NHMRC project grant (631567).

## References

- [1]C. Schiepers, W. Chen, T. Cloughesy, M. Dahlbom and S. C. Huang, Journal of Nuclear Medicine, 2007, 48(10):1651
- [2]Y. Gal, A. Mehnert, A. Bradley, K. McMahon and S. Crozier, IEEE Engineering in Medicine and Biology Society (EMBC), 2007, 71-74
- [3]E. Eyal and H. Degani, NMR in Biomedicine, 2009, 22(1):40-53
- [4]Y. Gal, A. Mehnert, A. Bradley, D. Kennedy and C. Stuart, Journal of Computer Assisted Tomography, 2010, 35(5):645-654
- [5]S. Bisdas, T. Naegele, R. Ritz, A. Dimostheni, C. Pfannenberger, M. Reimold, T. S. Koh and U. Ernemann, Academic Radiology, 2011, 18(5):575-583



**Figure 1: Classification results of the two patients that has gone through radio-therapy at time points T2 and T3 (patient 1 on the left, patient 2 on the right): The arrows denote places where contrast enhancement is clearly seen in the CE MRI while weak or no enhancement is shown in the FDOPA and the risk map images. In the risk map, bright orange corresponds to high risk (i.e. higher than 0.75) while dark red corresponds to low risk (i.e. lower than 0.5).**