

Investigation of a drug with potential fast-onset efficacy in affective disorders: pharmacological MRI of the 5-HT_{2A} receptor agonist psilocyn in the rat.

Aisling Spain¹, Alexandre Khrapitchev¹, Trevor Sharp², Nicola R. Sibson¹, and Chris Martin¹

¹Gray Institute for Radiation Oncology and Biology, University of Oxford, Oxford, Oxfordshire, United Kingdom, ²Department of Pharmacology, University of Oxford, Oxford, Oxfordshire, United Kingdom

Introduction

A major shortcoming in existing pharmacological treatments for mood disorders, such as depression and anxiety, is their delayed onset of action. Two to three weeks of treatment may be required before symptoms are relieved. Hallucinogenic drugs have potential applications as fast-acting treatments for depression or anxiety disorders (Vollenweider & Kometer, 2010). However, the legal status of these drugs has restricted research in this area in the past but increasing awareness of the shortcomings of current treatments for affective disorders, along with the possibilities for concurrent assessment of affective and physiological effects offered by fMRI has renewed research interest in them. A pilot study of the efficacy of psilocybin, the hallucinogenic compound present in “magic” mushrooms, in anxiety, has yielded promising results (Grob et al., 2011) and the drug has been demonstrated to be well tolerated in subjects undergoing a simulated MRI environment (Carhart-Harris et al., 2010). Characterisation of an imaging biomarker for the efficacy of hallucinogenic drugs in affective disorders would be useful in the further development of drugs with fast-acting efficacy, particularly in an animal model, where further investigation of mechanisms underlying the behavioural and physiological effects of these drugs is possible. We therefore conducted pharmacological MRI (phMRI) based on the blood oxygen level dependent (BOLD) contrast mechanism in rats to determine the functional effects of administration of the selective serotonin (5-HT) 2A receptor agonist psilocyn, the active metabolite of psilocybin.

Methods

Imaging was performed on a 9.4T horizontal-bore magnet (Varian) using a 2-channel birdcage coil (Insight Neuroimaging). Functional data were acquired using a T2*-weighted multi-echo gradient-echo sequence (6 echoes with even spacing between 3 and 18ms, TR=625ms, field of view 32 X 32 mm, matrix size 96 X 96, slice thickness 0.5mm, 26 axial slices). Images were averaged across echoes to improve SNR and the 26 slice volume was acquired in 60s and 60 volumes were acquired for each experiment. Psilocyn (2mg/kg, dissolved in 0.05mM tartaric acid) was injected intravenously after a 15 minute period of baseline data acquisition. FMRI data processing was carried out using FEAT (FMRI Expert Analysis Tool) Version 5.92, part of FSL (FMRIB's Software Library, www.fmrrib.ox.ac.uk/fsl). Z (Gaussianised T/F) statistic images were thresholded using clusters determined by Z>2.3 and a (corrected) cluster significance threshold of P=0.05 (Worsley, 2001). The design matrix consisted of a simple off→on (pre→post drug) component and a covariate based on time-series changes in non-brain tissue to help account for systemic drug effects. Higher level analysis was carried out using FEAT to determine results across the entire group.

Results

Psilocyn administration was associated with widespread increases in BOLD signal. Significant increases in BOLD signal were observed in prefrontal (Figure 1A) and subcortical (Figure 1B) regions, including the nucleus accumbens, amygdala and hippocampal CA1 and CA3.

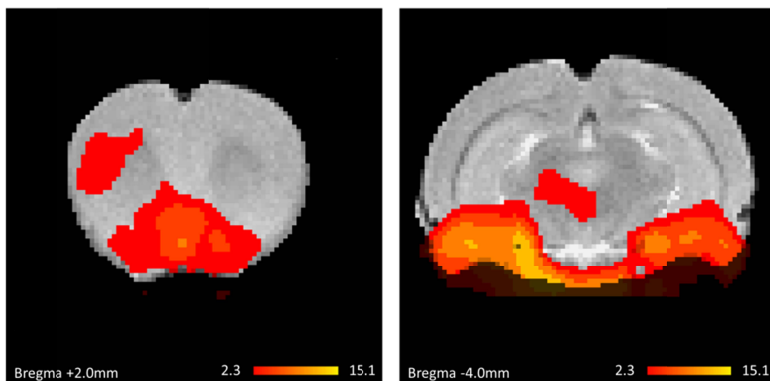


Figure 1: Psilocyn administration was associated with significant increases in BOLD signal in prefrontal areas including the nucleus accumbens (A) and subcortical areas including the amygdala and hippocampal subfields (B). Activation overlays denote increases in BOLD signal amplitude corresponding to a z-score >2.3, magnitude of increases is indicated by the intensity bar.

Discussion

Acute psilocyn administration was associated with significant BOLD signal alterations in prefrontal and subcortical areas that have previously been implicated in the pathophysiology of depression in other brain imaging studies in humans (Hasler et al., 2011). The observation of acute psilocyn-induced haemodynamic changes in regions of the brain relevant to mood disorders may offer a clue as to how such drugs exert antidepressant and anxiolytic effects. This study also demonstrates the potential utility of fMRI as a translational biomarker for screening drugs with short-onset efficacy in affective disorders. Future work will seek to elucidate both the pharmacological specificity of the effects seen here as well as the relationship of these effects to other haemodynamic (e.g. cerebral blood flow) and neuronal activity measures.

References

Carhart-Harris et al. (2010). J.Psychopharmacol.
Grob et al. (2011). Arch Gen Psychiat. 68: 71
Hasler et al. (2011). Mol Psychiat. 16: 604

Vollenweider & Kometer (2010). Nature Rev Neurosci. 11: 642
Worsley (2001). in Functional MRI: An Introduction to Methods