

High Resolution Sodium MRI and Abnormal Sodium Ion Pump in the Bipolar Brain

Fernando Emilio Boada¹, Vincent Lee¹, Yongxian Qian¹, Mary Phillips², and David Kupfer²

¹Radiology and Bioengineering, University of Pittsburgh, Pittsburgh, PA, United States, ²Psychiatry, University of Pittsburgh, Pittsburgh, PA, United States

INTRODUCTION

Bipolar Disorder (BPD) is a debilitating disease that affects about 4% of the population in the United States. The disease presents itself during early adulthood and leads to severe disability when left untreated. One of the potential explanations for the pathophysiology of BPD includes the Na-K-ATPase dysfunction theory [1]. This theory states that lower sodium ion pump function is the leading cause of BPD and that lithium treatment regulates the disease by limiting the concomitant increase in intracellular sodium content. Because of its life-threatening side effects, lithium treatment requires a dose escalation regimen aimed at establishing a serum lithium concentration (SLC) in the range of 0.5-1.0mM. This serum level is monitored using regular blood sampling but the strategy is of limited success because the drug uptake from blood varies considerably from individual to individual, and with age [2]. One corollary of the ion pump dysfunction theory, with important treatment implications, is that successful lithium treatment should lead to a normalization of the brain sodium content (BSC) in BPD subjects. To study the relevance of this corollary for treatment, a necessary first step is the characterization of the brain sodium content of stable BPD subjects. We demonstrate the use of High-Resolution, Ultra-High-Field (UHF) sodium imaging for studying the differences in sodium content between the brain of stable BPD and normal subjects. Our results suggest higher BSC in the basal ganglia of lithium-treated euthymic BPD subjects.

METHODS

Euthymic bipolar (N=8) and normal control (N=8) subjects were scanned on a whole body Magnetom TIM 7 Tesla scanner (Siemens AG, Erlangen, Germany) using an approved Institutional Review Board (IRB) protocol. The imaging protocol included the acquisition of Gradient recalled (GRE) and high-resolution T1 (MPGRAGE) proton images for co-registration and volumetric analysis, as well as sodium and lithium MRI. The high-resolution sodium data set was acquired using a twisted projection imaging (TPI) sequence [3] and a home-built, 15-channel single-tuned coil (TE/TR=0.3/100ms, Voxel=0.008cc, 3 Averages, 12 minutes). The lithium data set, on the other hand, was acquired using a single-tuned, 8-channel RF coil (Stark Contrast, Erlangen, Germany). Because of the self-calibrated nature of the TPI sequence, a conjugate gradient sensitivity-encoding (SENSE) scheme was used (without additional data) to remove the coil sensitivity modulation from the high-resolution images. After SENSE reconstruction, all images were spatially-normalized and co-registered to their corresponding group using an affine transformation. Pixel-wise analysis was then used to identify areas with potential differences followed by segmentation-based regional analysis.

RESULTS

Figure 1 presents selected partitions from the spatially-normalized results from the normal (top) and BPD (bottom) subject groups. The darker basal ganglia (lower concentration) are already evident in the brain of the bipolar subjects. Figure 2 shows a more detailed look at these changes by presenting a comparison between line profiles (left) taken along the line depicted in the figure (right). Most of the observed changes occur in the deep brain with gray matter cortex appearing to have comparable in concentration.

CONCLUSIONS

This study supports the hypothesis that higher regional BSC is characteristic of the brain of BPD subjects. The relationship between this higher BSC and lithium deposition is currently under investigation and could be the basis for an imaging-based correlate of successful treatment.

REFERENCES: [1] El-Mallakh RS, et al., Biol. Psych., **37**: 235, 1995. [2] Forester BP, et al., Bipolar Disord., **10**:691, 2008. [3] Boada FE et al., MRM, **37**:706, 1997. **Supported in part by PHS Grant R01-MH088370-01.**

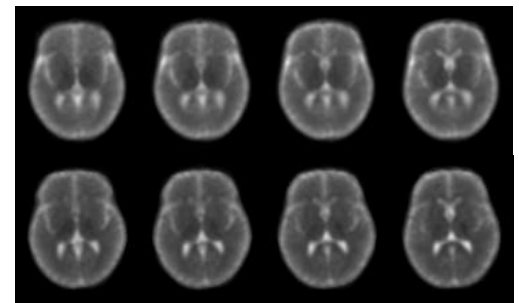


Figure 1: Selected partitions from spatially normalized sodium scans for Normal (top) and BPD groups (bottom). The lower concentration in the basal ganglia is evident in these images.

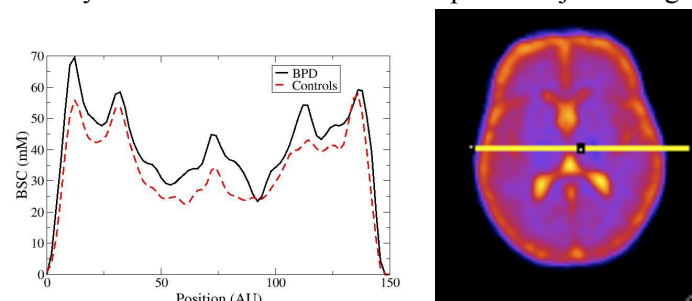


Figure 1: (left) Plot of the signal intensity along the line depicted in the image (right). The higher BSC is evident in the basal ganglia.