

IMAGING OF NEONATAL BRAIN DEVELOPMENT USING ARTERIAL SPIN LABELING MRI.

Jill B De Vis¹, Manon JNL Benders², Linda S de Vries², Floris Groenendaal², Karina J Kersbergen², Thomas Alderliesten², Jeroen Hendrikse¹, and Esben T Petersen¹
¹Radiology, University Medical Center, Utrecht, Utrecht, Netherlands, ²Neonatology, University Medical Center, Utrecht, Netherlands

Introduction: Neuro-imaging has provided information about normal and abnormal brain development in neonates. In the past, Positron Emission Tomography (PET) studies [1] have shown that patterns of brain glucose metabolism appear to be related to postconceptional age and undergo marked changes in the first year of life correlated with the anatomical and functional maturation of the brain. The highest rates of glucose metabolism in the newborn brain were seen in the primary sensory and motor cortex, thalamus, brain stem and vermis, hippocampus/amygdala and the basal ganglia, with very low activity noted in the remaining cerebral cortex. At 2-3 months an increase in glucose metabolism was seen in the parietal, temporal and primary visual cortex, basal ganglia and cerebellar hemispheres[2]. Arterial Spin Labeling (ASL) Magnetic Resonance Imaging (MRI) -which uses radiofrequency pulses to magnetically label the blood- enables us to non-invasively assess Cerebral Blood Flow (CBF) in different brain regions and can be used to evaluate brain development. ASL imaging may be helpful in detecting changes in regional blood flow at an earlier stage, before the development of structural and morphological abnormalities. The objective of this study was to evaluate perfusion in different brain regions from preterm until 3 months after term equivalent age.

Materials and methods: Pulsed ASL images (Philips 3T, 8-channel head coil) were acquired of 16 infants without brain injury on conventional imaging; FOV 192x192 mm², SENSE 2.5, 9 slices, 3x3x6mm, TR/TE/TI: 2500/20/1800 msec and Q2-TIPS [3]. One infant was imaged at 31 weeks postmenstrual age (PMA), 12 infants at 40 weeks PMA and 3 infants at 50 weeks PMA. In addition, for accurate CBF quantification, the T1 of blood was measured [4] thereby accounting for the large variation of hematocrit in neonates. Regions of interest (ROI) were manually drawn within the occipital cortex, the frontal cortex and one ROI covered the basal ganglia and thalamus.

Results: Acceptable image quality was obtained in 14 infants (Fig.1). Mean perfusion values were calculated for the basal ganglia and thalamus, the occipital cortex and frontal cortex at different PMA (resp.30,40 and 50 wks). The highest perfusion was measured in the basal ganglia and thalamus. An increase in total perfusion was measured from 40 to 50 wks PMA (Table 1). Perfusion values in the different brain regions were also expressed relative to total brain perfusion; a relative decrease in perfusion towards the basal ganglia and thalamus and a relative increase in perfusion towards the occipital and frontal cortex was measured with increase in PMA (Fig.2).

Discussion and conclusion: Perfusion images could be obtained with pulsed ASL in preterm infants, term infants and in 3 months old neonates. Perfusion values measured at different PMA reflect the anatomical and functional maturation of the brain and are in agreement with the images of glucose metabolism obtained previously in PET-studies. Early detection of the presence of abnormalities in perfusion of the brain using a non-invasive technique such as ASL imaging may be used to detect developmental abnormalities. Furthermore, early detection of brain injury secondary to intrauterine and perinatal insults using ASL may give new insights in pathophysiology, prognosis and maybe in instituting early therapy.

References: [1] Chugani et al. Prev Med 1998; 27(2): 184-188. [2]Kinnala et al. Archives of disease in childhood fetal and neonatal edition 1996; 74. [3] Luh et al. Radiology 1994; 192(2): 513-520. [4] Varela et al. NMR Biomed 2011;24:80-88.

Acknowledgement: This research is supported by the Dutch Technology Foundation STW, applied science division of NWO and the Technology Program of the Ministry of Economic Affairs.

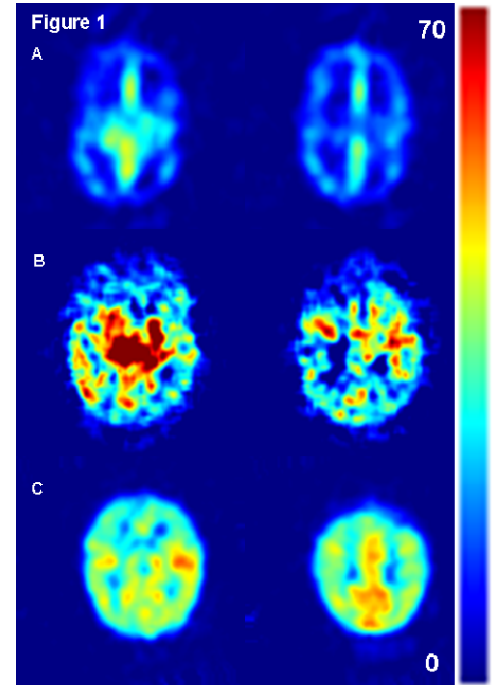


Fig.1: A) ASL images of an infant imaged at 31 wks PMA. B) ASL images of an infant imaged at 40 wks PMA. C) ASL images of the same infant as in B, but now imaged at 50 wks PMA.

PMA		BG	OC	FC	Total
30 weeks	Mean	37,00	13,00	13,00	17,00
	N	1	1	1	1
40 Weeks	Mean	31,10	15,90	13,30	16,00
	N	10	10	10	10
	Std. Deviation	14,30	5,216	4,968	6,342
50 Weeks	Mean	42,33	31,33	26,33	30,00
	N	3	3	3	3
	Std. Deviation	4,163	3,512	3,055	2,646

Table 1: Mean perfusion values (in ml/100g.min) for different brain regions at different PMA; BG=Basal ganglia and thalamus, OC=Occipital Cortex, FC= Frontal Cortex.

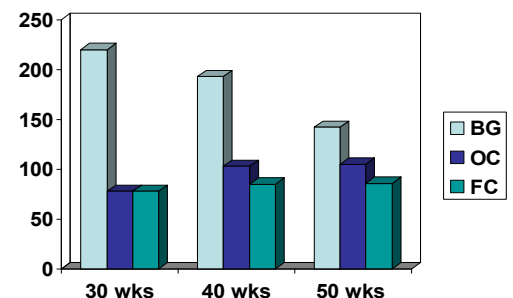


Fig.2: Perfusion expressed relative towards the entire brain perfusion at different PMA (resp. 30, 40 and 50 wks).BG=basal ganglia and thalamus, OC=occipital Cortex and FC=Frontal Cortex.