

# WHITE MATTER DEVELOPMENT IN PRETERM AND TERM INFANTS ASSESSED BY DIFFUSION TENSOR IMAGING WITH TRACT-BASED SPATIAL STATISTICS

Hou Xin<sup>1</sup>, Li Xianjun<sup>2</sup>, Gao Jie<sup>1</sup>, Sun Qinli<sup>1</sup>, Yu Bolang<sup>1</sup>, Ed X. Wu<sup>3</sup>, Wan Mingxi<sup>2</sup>, and Yang Jian<sup>1,2</sup>

<sup>1</sup>Department of radiology, the First Affiliated Hospital of Medical College of Xi'an Jiaotong University, Xi'an, Shannxi, China, People's Republic of, <sup>2</sup>Department of Biomedical Engineering, School of Life Science and Technology, Xi'an Jiaotong University, Xi'an, Shannxi, China, People's Republic of, <sup>3</sup>Laboratory of Biomedical Imaging and Signal Processing, The University of Hong Kong, Hong Kong SAR, China, People's Republic of

## Introduction

Although white matter (WM) develops from embryonic period to adulthood, the most rapid and important stage is from the third trimester of pregnancy to the neonatal period [1]. The different microstructures between preterm and term brain can provide insights into the brain development during this period evidently. Diffusion tensor imaging (DTI) is a novel method to detect WM development with fractional anisotropy (FA), axial diffusivity (AD), radial diffusivity (RD) and mean diffusivity (MD) [2,3]. In this study, we aimed to employ DTI with tract-based spatial statistics (TBSS) to investigate the WM changes in preterm and term neonates with post-menstrual ages (PMA).

## Materials and Methods

44 healthy neonates were enrolled prospectively, including 24 term infants (mean PMA: 39.58±1.74 weeks) and 20 preterm infants (mean PMA: 35.39±0.90 weeks). The infants were sedated during imaging with oral chloral hydrate (25-50 mg/kg) with parental consent and approval from local institutional ethics committee. 3D

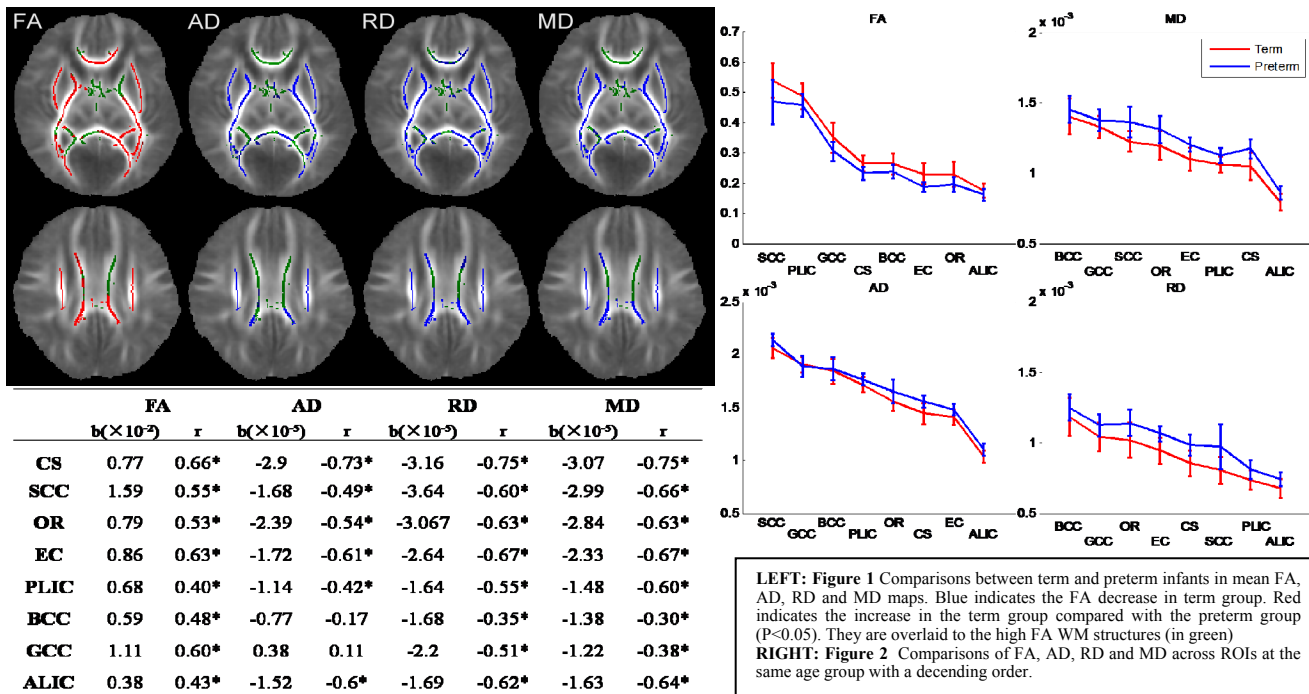


Table 1 Correlations between FA, AD, RD and MD values and PMA. b is slope of the line, and r the correlation coefficient (\* P<0.05).

magnetization prepared rapid gradient echo (3D-MPRAGE) T1WI, and fast spin echo (FSE) T2WI and DTI by single shot echo planar sequence were performed in a 3T scanner (GE, Signa HDxt.) with 8-channel high-resolution radio-frequency head coil within 28 days after birth in each neonates. DTI was performed with 35 diffusion directions, SENSE factor = 2, TR/TE=5500/95ms, slice thickness=4 mm without gap, field of view = 180mm, matrix = 256×256 (voxel size= 0.70×0.70×4mm<sup>3</sup>), b value=1000s/mm<sup>2</sup>. DTI data was analyzed using TBSS [4] using FMRIB (FSL) [5]. Extracted brain images were acquired using Brain Extraction Tool (BET/FSL) [6]. FMRIB Diffusion Toolbox (FDT) [7] was used to carry out eddy current correction. Each aligned FA image of each subject was projected onto the mean FA map (threshold = 0.2) before applying voxel-wise cross-subject statistics. The analysis was fully corrected for multiple comparisons across space using threshold free cluster enhancement. All tests were considered to be significant at p<0.05. The regions of interest (ROIs) were selected manually on the mean FA map, including centrum semiovale (CS), splenium of corpus callosum (SCC), body of corpus callosum (BCC), posterior limb of internal capsule (PLIC), external capsule (EC), optic radiation (OR), anterior limb of internal capsule (ALIC), and genu of corpus callosum (GCC). In each ROI, correlation between DTI index and PMA was analyzed in Matlab (MathWorks).

## Results and Discussions

Compared with preterm brain, FA values increased while AD, RD, and MD values decreased significantly in most regions of the term WM except GCC (AD and MD), and BCC (AD and MD) (P<0.05) (Figure 1). Figure 2 shows the comparisons of diffusion values between term and preterm infants. FA and AD of SCC were higher while MD and RD were lower than GCC and BCC, indicating a posterior-to-anterior trend of axon development and myelination as suggested by previous studies of brain development [8]. However, ALIC exhibited the lowest diffusion values, likely reflecting the short and unmyelinated axons in the region. During this period, ALIC axons are known to be unordered and hypoplastic. Table 1 summarizes the correlations between various diffusion values in each ROI with PMA, showing the positive FA correlation and negative AD, RD, MD correlation with PMA. The correlation slopes (denoted as b values) of SCC, CS, OR, and EC were significant higher than those in other regions, indicating rapid white matter development during this period. In conclusion, our results demonstrated that the white matter development of SCC, CS, OR, and EC was rapid during neonatal period.

## Acknowledgements

The authors would like to thank Drs. He Wang, Zhikui Xiao and Guang Cao from Applied Science Lab, GE Healthcare for their technical assistance. This study was supported by a grant from National Natural Science Foundation of China (No. 30970797 to JY).

## References

- [1] Sidman RP, et al. Histology and Histopathology of the Nervous System, 1982. [2] Huppi PS, et al. Semi Fetal Neonatal Med, 2006. [3] Gao W. AJNR, 2009. [4] Smith SM, et al. NeuroImage, 2006. [5] Smith SM, et al. NeuroImage, 2004. [6] Smith SM. Human Brain Mapping, 2002. [7] Behrens TEJ, et al. Magn Reson Med, 2003. [8] Gilmore JH, et al. AJNR, 2007.