

## Exploring the Relationship Between Regional Gray Matter Atrophy and Cognitive Impairment in Pediatric Multiple Sclerosis

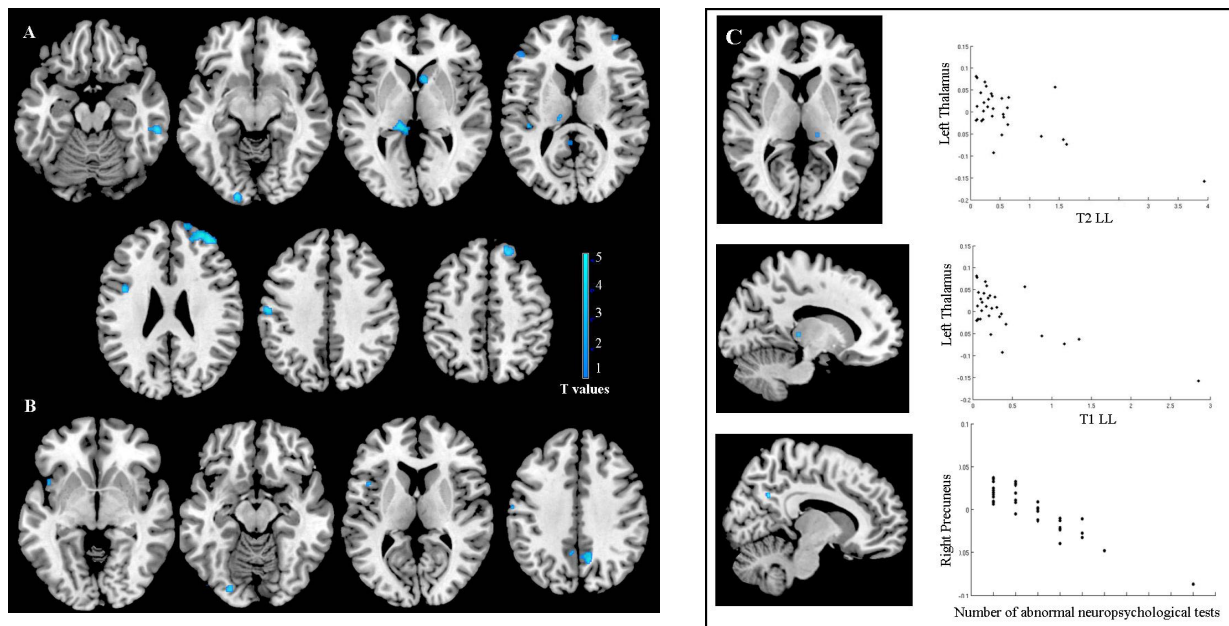
Martina Absinta<sup>1</sup>, Maria A. Rocca<sup>1</sup>, Maria Pia Amato<sup>2</sup>, Angelo Ghezzi<sup>3</sup>, Lucia Moiola<sup>4</sup>, Agnese Fiorino<sup>4</sup>, Pierangelo Veggiotti<sup>5</sup>, Andrea Falini<sup>6</sup>, Giancarlo Comi<sup>4</sup>, Massimo Filippi<sup>1</sup>, and the MS and Neuroimaging Study Groups of the Italian Neurological Society<sup>7</sup>

<sup>1</sup>Neuroimaging Research Unit, Institute of Experimental Neurology, San Raffaele Scientific Institute and Vita-Salute San Raffaele University, Milan, Italy, Italy, <sup>2</sup>Department of Neurology, University of Florence, <sup>3</sup>MS Centre, Ospedale di Gallarate, <sup>4</sup>Department of Neurology, San Raffaele Scientific Institute and Vita-Salute San Raffaele University, Milan, Italy, Italy, <sup>5</sup>Department of Child Neurology and Psychiatry, Fondazione IRCCS Istituto Neurologico C Mondino, <sup>6</sup>Department of Neuroradiology, San Raffaele Scientific Institute and Vita-Salute San Raffaele University, Milan, Italy, Italy, <sup>7</sup>.....

**Introduction.** Cognitive impairment affects more than 30% of patients with pediatric multiple sclerosis (MS), with involvement of attention, language, visual-spatial functions, spatial memory, executive functions and abstract reasoning.<sup>1,2</sup> Aim of this study is to assess the patterns of regional abnormalities in the brain gray matter (GM) and white matter (WM) in pediatric MS patients according to their cognitive profile, using voxel-based morphometry (VBM).

**Methods.** Using a 3.0 Tesla scanner, brain dual-echo and 3D T1-weighted scan were acquired from 35 pediatric MS patients (22 girls, mean age=15.3 years, median EDSS=1.5, mean disease duration=2.1 years) and 16 gender- and age-matched controls. All patients underwent a neuropsychological assessment and patients with at least two abnormal tests were considered as cognitively impaired (CI). T2 and T1 lesion loads (LL) were calculated using Jim5 software. After refilling of T1-hypointense lesions<sup>3</sup> on the 3D T1-weighted images, VBM was performed using SPM8 and DARTEL<sup>4,5</sup> ( $p < 0.001$ , cluster extent 10 voxels).

**Results.** Sixteen pediatric MS patients were CI. Compared to controls, pediatric MS patients had a significant atrophy of the left (L) thalamus, L lingual gyrus, several regions in the frontal lobes, right (R) caudate nucleus, L postcentral gyrus (PcG), R inferior temporal gyrus and L superior temporal gyrus (Figure A). Compared to controls and to cognitively preserved patients, CI patients had more severe atrophy of the bilateral precuneus, L lingual gyrus, L inferior frontal operculum, L insula, L middle temporal gyrus, and L PcG (Figure B). In pediatric MS patients, thalamic atrophy was significantly related to T2-LL ( $r = -0.52$ ,  $p < 0.001$ ) and T1-LL ( $r = -0.58$ ,  $p < 0.001$ ), while R precuneus atrophy correlated with the number of abnormal neuropsychological tests ( $r = -0.57$ ,  $p < 0.001$ ) [Figure C].



**Conclusions.** In pediatric MS, GM atrophy is not limited to the thalamus (whose damage is strongly related to focal lesion burden), but also involves several cortical and subcortical regions. The assessment of the regional distribution of GM atrophy contributes explaining cognitive deficits in these patients.

### References

[1] Portaccio et al., *Neurol Sci* 2010; [2] Goretti et al., *Mult Scler* 2011; [3] Chard et al., *J Magn Reson Imaging* 2010; [4] Ashburner et al., *Neuroimage* 2005; [5] Ashburner et al., *Neuroimage* 2007.

**This work has been partially supported by a grant from Italian Ministry of Health (GR-2009-1529671).**